

The Diagnosis And Treatment of Heel Pain

A CLINICAL PRACTICE GUIDELINE
REVISION 2010

Disclaimer

This Clinical Practice Guideline is the 2010 revision of an original guideline published in 2001 in the *Journal of Foot & Ankle Surgery*. It was developed by a panel of ACFAS physician volunteers based on consensus of current clinical practice and review of the clinical literature. It provides information and accepted approaches to treatment and/or diagnosis. It is not intended to be a fixed protocol, as some patients may require more or less treatment or different means of diagnosis. Patient care and treatment should always be based on a clinician's independent medical judgment, given an individual patient's clinical circumstances.

A collection of all ACFAS Clinical Practice Guidelines appears online at acfas.org/CPG.




Proven leaders. Lifelong learners. Changing lives.



Contents lists available at ScienceDirect

The Journal of Foot & Ankle Surgery

journal homepage: www.jfas.org



Clinical Practice Guideline

The Diagnosis and Treatment of Heel Pain: A Clinical Practice Guideline–Revision 2010

James L. Thomas, DPM¹, Jeffrey C. Christensen, DPM², Steven R. Kravitz, DPM³, Robert W. Mendicino, DPM⁴, John M. Schuberth, DPM⁵, John V. Vanore, DPM⁶, Lowell Scott Weil Sr, DPM⁷, Howard J. Zlotoff, DPM⁸, Richard Bouché, DPM⁹, Jeffrey Baker, DPM¹⁰

¹ Chair, Clinical Practice Guideline Heel Pain Panel (2001), Morgantown, WV

² Clinical Practice Guideline Heel Pain Panel (2001), Seattle, WA

³ Clinical Practice Guideline Heel Pain Panel (2001), Richboro, PA

⁴ Clinical Practice Guideline Heel Pain Panel (2001), Pittsburgh, PA

⁵ Clinical Practice Guideline Heel Pain Panel (2001), San Francisco, CA

⁶ Clinical Practice Guideline Heel Pain Panel (2001); Gadsden Foot Clinic PC, Gadsden, AL

⁷ Clinical Practice Guideline Heel Pain Panel (2001), Des Plaines, IL

⁸ Clinical Practice Guideline Heel Pain Panel (2001), Mechanicsburg, PA

⁹ 2009 Advisor, Seattle, WA

¹⁰ 2009 EBM contribution, Des Plaines, IL

ARTICLE INFO

Keywords:

Achilles enthesopathy
 Achilles tendonitis
 calcaneal enthesopathy
 heel neuroma
 heel pain
 heel spur syndrome
 plantar fasciitis
 radiculopathy
 spur
 tarsal tunnel

ABSTRACT

Heel pain, whether plantar or posterior, is predominantly a mechanical pathology although an array of diverse pathologies including neurologic, arthritic, traumatic, neoplastic, infectious, or vascular etiologies must be considered. This clinical practice guideline (CPG) is a revision of the original 2001 document developed by the American College of Foot and Ankle Surgeons (ACFAS) heel pain committee.

© 2010 by the American College of Foot and Ankle Surgeons. All rights reserved.

This clinical practice guideline (CPG) is based on consensus of current clinical practice and review of the clinical literature. The guideline was developed by the CPG Heel Pain Committee of the American College of Foot and Ankle Surgeons (ACFAS). This is the 2010 revision of the original 2001 CPG document published in the *Journal of Foot & Ankle Surgery*® (Vol. 40, No. 5, pages 329–340). The guideline and references annotate each node of the corresponding pathways.

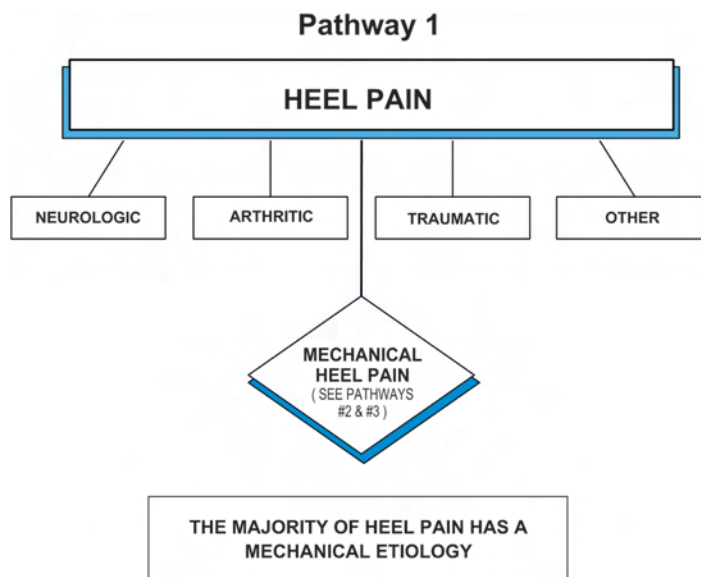
Financial Disclosure: None reported.

Conflict of Interest: Dr. Weil discloses consultant, advisory, and legal expert roles, as well as research funding, in association with ArthroCare Corporation, Orthometrix Inc., and Electro Medical Systems SA. Dr. Bouché discloses a proprietary interest in United Shockwave Therapies, LLC. Dr. Vanore discloses a consultant/advisory role with BME-TX and Ascension Orthopedics, stock ownership in BME-TX, and receipt of honoraria from BME-TX.

Supplement to: *The Journal of Foot & Ankle Surgery*®

Address correspondence to: John V. Vanore, DPM, Gadsden Foot Clinic PC, 306 S. 4th Street, Gadsden, AL 35901.

E-mail address: jvanore@bellsouth.net (J.V. Vanore).



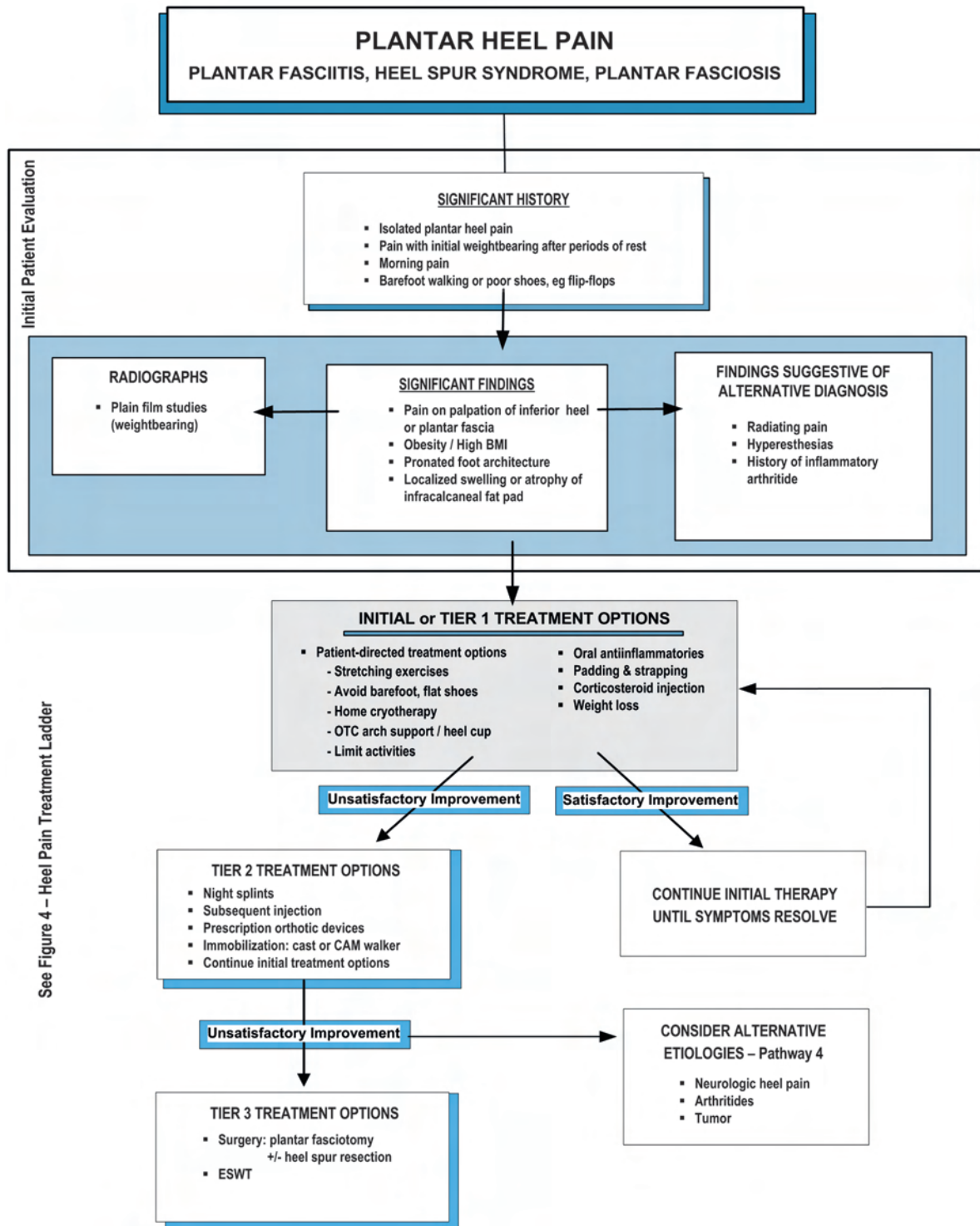
Heel Pain (Pathway 1)

The heel is a frequent area of pathology. Pain in the heel may be the result of arthritic, neurologic, traumatic, or other systemic conditions, although the overwhelming cause is mechanical in origin. Careful history and examination are generally indicative of etiology and appropriate diagnostic testing will lead to accurate diagnosis. Treatment is directed toward causative factors.

Plantar Heel Pain [Plantar Fasciitis, Plantar Fasciosis, Heel Spur Syndrome] (Pathway 2)

Plantar heel pain is the most prevalent complaint presenting to foot and ankle specialists and may be seen in upwards of 11% to 15% of adults (1). Plantar heel pain has been referred to in the published literature by many names including heel spur syndrome, which lends some importance to the radiographic presence of an inferior calcaneal spur to the

Pathway 2



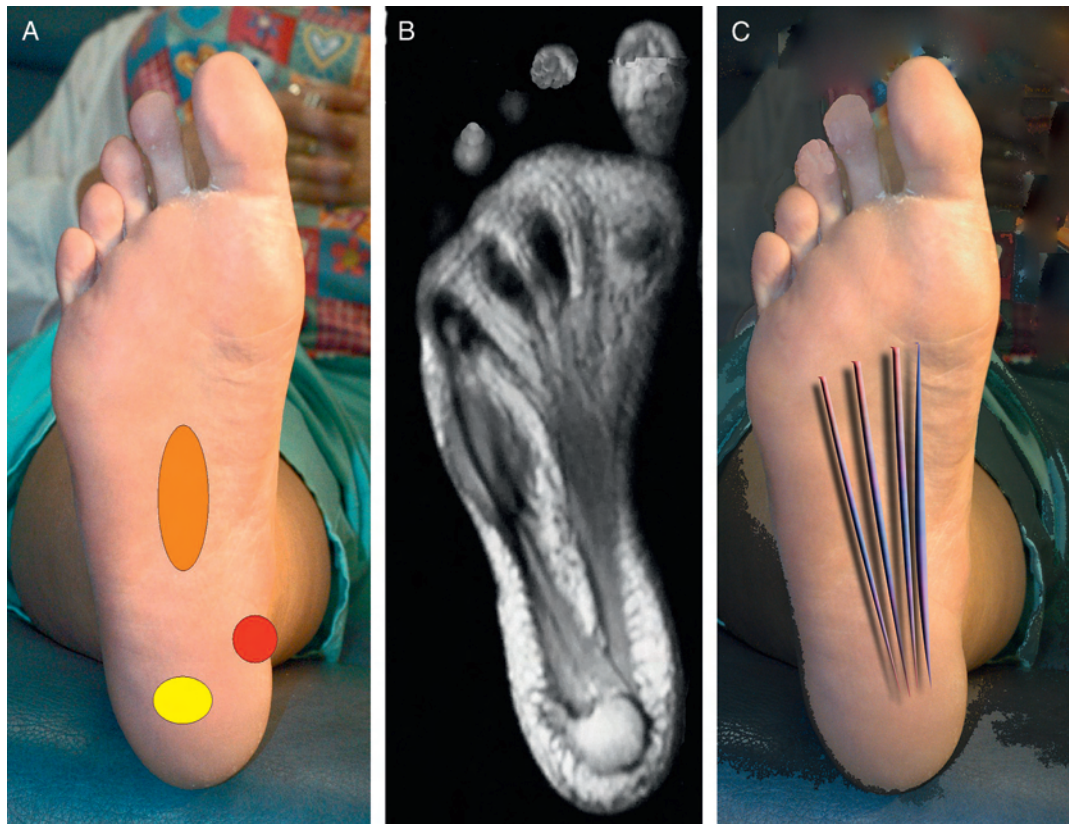


Fig. 1. (A) With plantar fasciitis, tenderness may be localized centrally along the plantar fascia (orange oval), along the plantar medial tuberosity (red circle), or directly plantar to the calcaneal tuberosity (yellow oval). (B) The anatomy of the plantar fascia as shown through MRI. (C) Depicted here are the lines of tension of the plantar fascia and its majority insertional attachment to the medial calcaneal tuberosity.

clinical symptoms. The term plantar fasciitis has been used for years, likely in an attempt to recognize the actual symptoms occurring along the plantar fascia with or without concomitant presence of a spur. More recently, the term plantar fasciosis has been advocated to de-emphasize the presumed inflammatory component and reiterate the degenerative nature of histologic observations at the calcaneal entheses (2, 3). Regardless of the exact terminology, the clinician, published literature, and general practice behaviors all describe the same pathology: pain along the proximal plantar fascia and its attachment in the area of the calcaneal tuberosity (Figure 1). The symptoms of plantar heel pain are well known, and diagnosis is relatively straightforward.

The most common cause cited for plantar heel pain is biomechanical stress of the plantar fascia and its entheses of the calcaneal tuberosity (Figure 2) (4–11). Mechanical overload, whether the result of biomechanical faults, obesity, or work habits, may contribute to the symptoms of heel pain. Discussion of a biomechanical etiology usually involves the windlass mechanism and tension of the plantar fascia in stance and gait (10, 12–21).

Localized nerve entrapment of the medial calcaneal or muscular branch off the lateral plantar nerve may be a contributing factor (22–43).

Patients usually present with plantar heel pain upon initiation of weight bearing, either in the morning upon arising or after periods of rest. The pain tends to decrease after a few minutes, and returns as the day proceeds and time on their feet increases. Associated significant findings may include high body mass index (BMI), tightness of the Achilles tendon, pain upon palpation of the inferior heel and plantar fascia, and inappropriate shoe wear (16, 18, 19, 31, 44–46).

Many patients will have attempted self-remedies before seeking medical advice. A careful history is important and should include

time(s) of day when pain occurs, current shoe wear, type of activity level both at work and leisure, and history of trauma. Presence of sensory disturbances including radiation of pain is generally indicative of neurologic pathology and is important to exclude. An appropriate physical examination of the lower extremity includes range of motion of the foot and ankle, with special attention to limitation of ankle dorsiflexion, palpation of the heel and plantar fascia, observation of swelling or atrophy of the heel pad, presence of hypesthesias or dyesthesias, assessment of the architectural alignment of the foot, and angle and base of gait evaluation. The quality and height of the plantar fat pad also have been implicated as factors in plantar heel pain (Figure 3) (47–51).

Following physical evaluation, appropriate radiographs (weight-bearing views preferred) may be helpful. Biomechanical interpretation of weight-bearing radiographs may provide insight into architectural faults. An infracalcaneal spur frequently is associated with the symptomatology of plantar fasciitis, although its presence or absence may not necessarily correlate with the patient's symptoms (52). Radiographic identification of a plantar heel spur usually indicates that the condition has been present for at least 6 to 12 months, whether having been symptomatic or asymptomatic (Figure 2). As a rule, the longer the duration of heel pain symptoms, the longer will be the period to final resolution of the condition (53, 54).

Initial treatment options (see Plantar Heel Pain Treatment Ladder, Figure 4) may include padding and strapping of the foot (45, 55), therapeutic orthotic insoles (56–62), oral anti-inflammatories (63), and a corticosteroid injection localized to the area of maximum tenderness (64–68). Patient-directed treatments appear to be as important as these approaches in resolving symptoms. Such

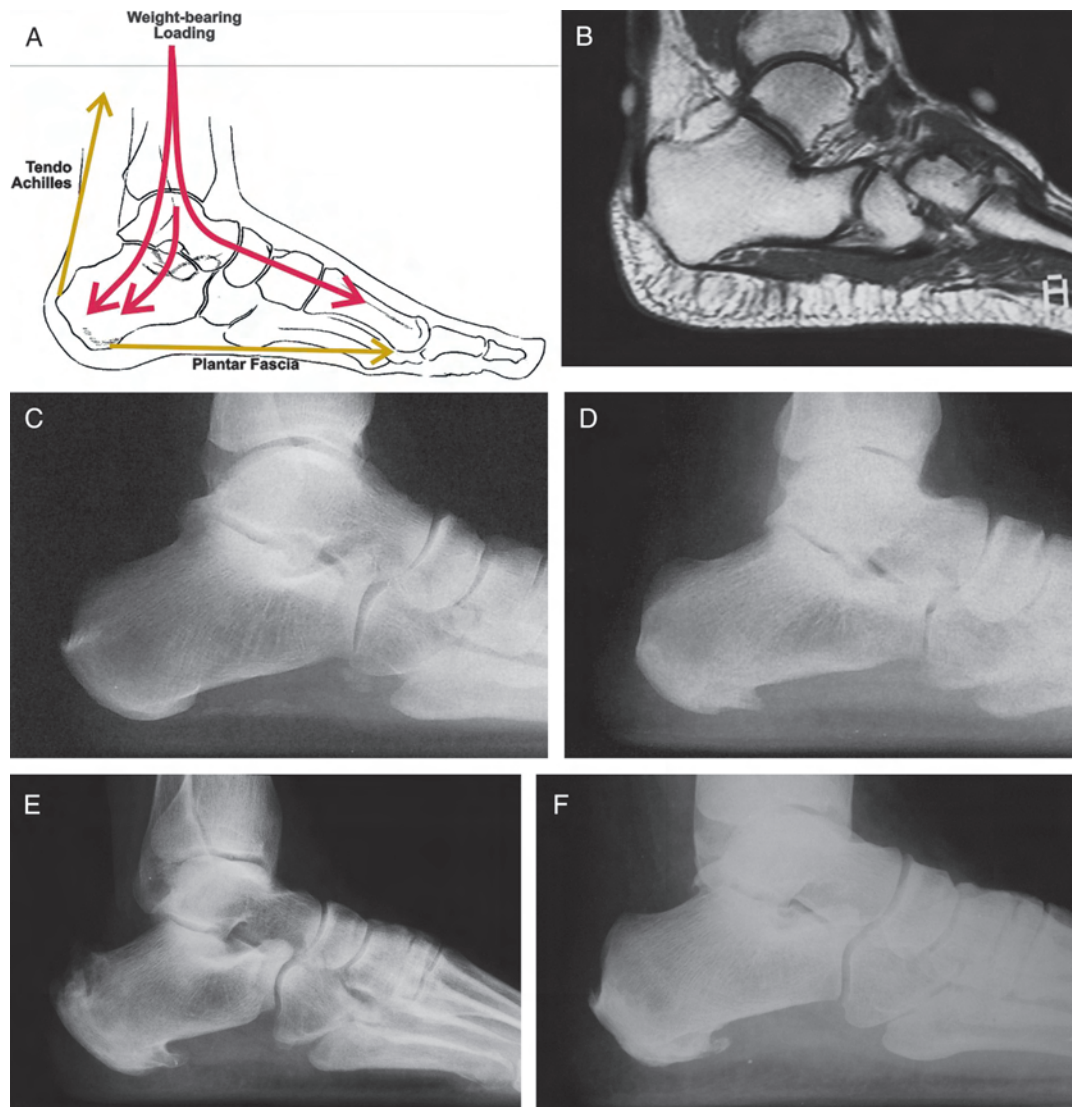

Fig. 2. Plantar heel pain often is related to (A) loading of the calcaneus and the tensile attachment of the plantar fascia, as shown in this MRI scan (B). (C) The weight-bearing lateral radiograph may or may not show an inferior os calcis spur. (D, E) The spur or enthesophyte begins small and may become very large, or on occasion, (F) may even fracture.

treatments include regular Achilles and plantar fascia stretching (69, 70), avoidance of flat shoes and barefoot walking, cryotherapy applied directly to the affected part, over-the-counter arch supports and heel cups, and limitation of extended (high-impact) physical activities (64, 71–73). Patients usually have a clinical response within 6 weeks of initiation of treatment. If improvement is noted, the initial therapy program is continued until symptoms are resolved. If little or no improvement is noted, the patient should be referred to a foot and ankle surgeon if not already under this specialist's care.

Treatment options have been graded according to the levels of evidence and grades of recommendation shown in Table 1 (74). Evidence-based medicine (EBM) conclusions regarding tier 1 therapies are as follows:

- Padding and strapping of the foot [Grade B recommendation] (45, 55)
- Therapeutic orthotic insoles [Grade B recommendation] (56–62)
- Oral inflammatory medication [Grade I recommendation] (63)
- Cortisone injections [Grade B recommendation] (64–68)

- Achilles and plantar fascia stretching [Grade B recommendation] (69, 70)

The second tier of the treatment ladder includes continuation of the initial (tier 1) treatment options with considerations for additional therapies: orthotic devices (75–78), night splints to maintain an extended length of the plantar fascia and gastroc-soleus complex during sleep (59, 61, 77, 79–93), repeat corticosteroid injection (2, 16, 45, 64, 65, 76, 79, 87, 94–109) or injection of botulinum toxin (110–117), a course of physical therapy (118), and cast immobilization for 4 to 6 weeks or use of a short-leg walking boot to immobilize or offload the foot during activity (64, 86, 119–121). In patients with a high BMI, a consultation and referral for an appropriate weight-loss program may be considered. Clinical response to this second tier of treatment will usually occur within 2 to 3 months in 85% to 90% of patients (17, 44, 46, 47, 122–128). For those who have shown improvement, continuation of tier 1 and tier 2 therapies should be continued until resolution of symptoms. Following a therapeutic regimen as outlined in Pathway 2, 90% to 95% of patients experience resolution of symptoms within 1 year

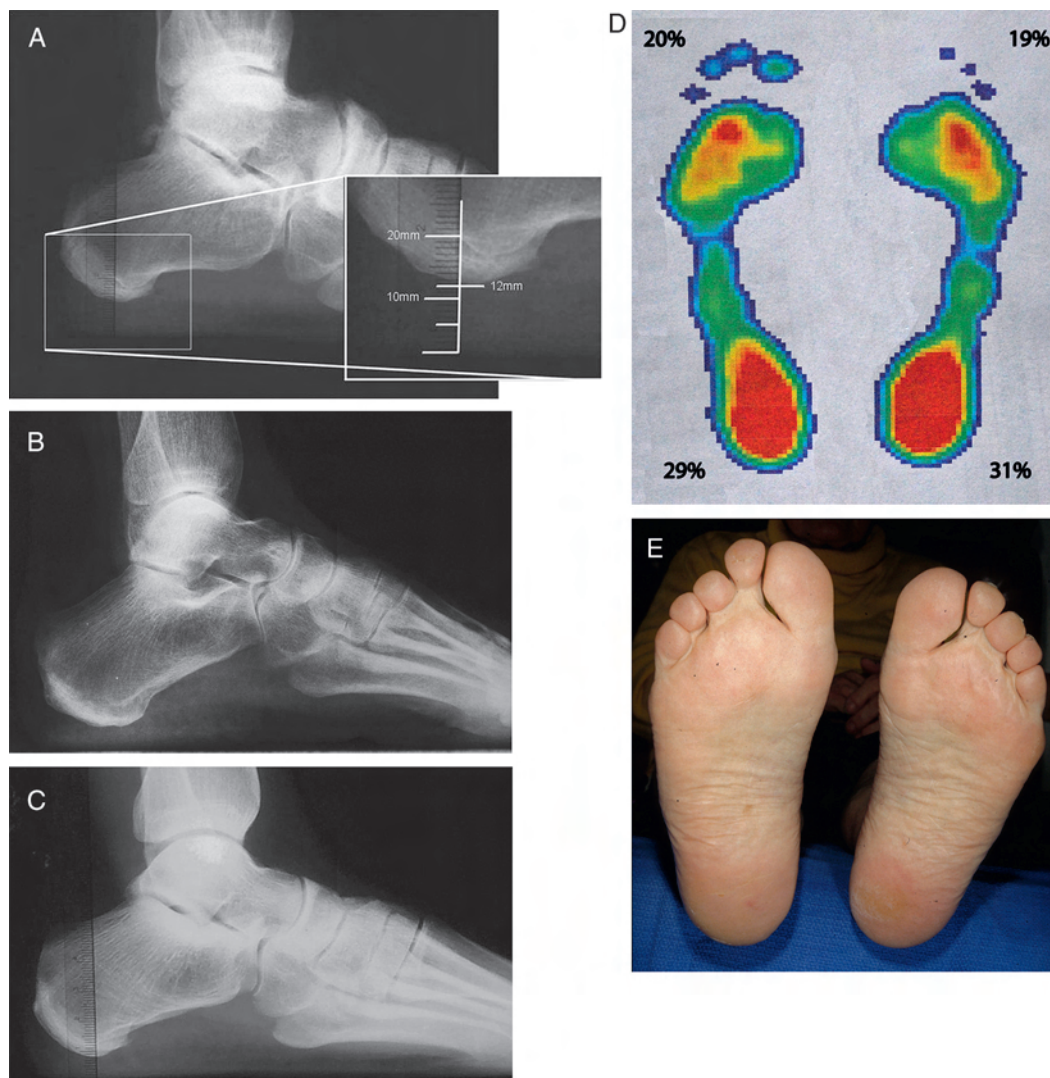

Fig. 3. (A) Plantar heel pain may be related to the height of the plantar fat pad, which may be determined from a weight-bearing lateral radiograph. In a slender or elderly individual this may be implicated as a causative factor. (B) This radiograph reveals a 6-mm height to the fat pad in a patient with a cavus architecture, whereas (C) this radiograph shows a patient who was measured at 8 mm in a more normal foot type. (D) Force plate or pressure analysis may demonstrate exaggerated loading of the heels, or (E) clinically the tuberosity may be easily palpable or callus may develop.

(128, 129). When little or no improvement is noted, other etiologic entities should be considered (130–142).

EBM conclusions regarding tier 2 therapies are as follows:

- Prefabricated and custom orthotic devices [Grade B recommendation] (75–78)
- Night splint [Grade B recommendation] (59, 61, 76, 77, 79–93)
- Repeat cortisone injections [Grade B recommendation] (2, 16, 45, 64, 65, 76, 79, 87, 94–109)
- Botulinum toxin [Grade I recommendation] (110–117)
- Physical therapy [Grade I recommendation] (118)
- Cast or boot immobilization [Grade C recommendation] (64, 86, 119–121)

The third tier of treatment continues tier 1 and/or 2 programs with consideration of surgical management. Options at this time may include surgical plantar fasciotomy using a recognized technique. This may entail endoscopic plantar fasciotomy, in-step fasciotomy, or minimally invasive surgical technique (129, 143–178) or extracorporeal shock wave therapy (ESWT) as an alternative to traditional

surgical approaches (64, 171, 179–206) (Figure 5). Current practice favors a minimally invasive approach to plantar fasciotomy versus extensive open surgical exposures (64, 129, 143–154, 156, 157, 163, 168–170, 174, 207–214). In most cases, removal of the plantar heel spur does not seem to add to the success of the outcome in the surgical treatment of plantar heel pain (151, 153, 165, 208).

In some cases, multiple etiologic factors including nerve entrapment may be implicated, necessitating the combination of nerve release and plantar fasciotomy (see Neurologic section, Pathway 4). Radiofrequency coblation of the plantar fascia as well as radiofrequency nerve ablation and cryoprobe have been advocated more recently as an alternative surgical approach to chronic heel pain (41, 42, 215–218).

EBM conclusions regarding tier 3 therapies are as follows:

- Endoscopic plantar fasciotomy, in-step fasciotomy, or minimally invasive surgical technique [Grade B recommendation] (64, 129, 143–154, 156, 157, 163, 168–170, 174, 207–214)
- ESWT [Grade B recommendation] (64, 171, 179–206)
- Bipolar radiofrequency [Grade C recommendation] (41, 42, 215–218)

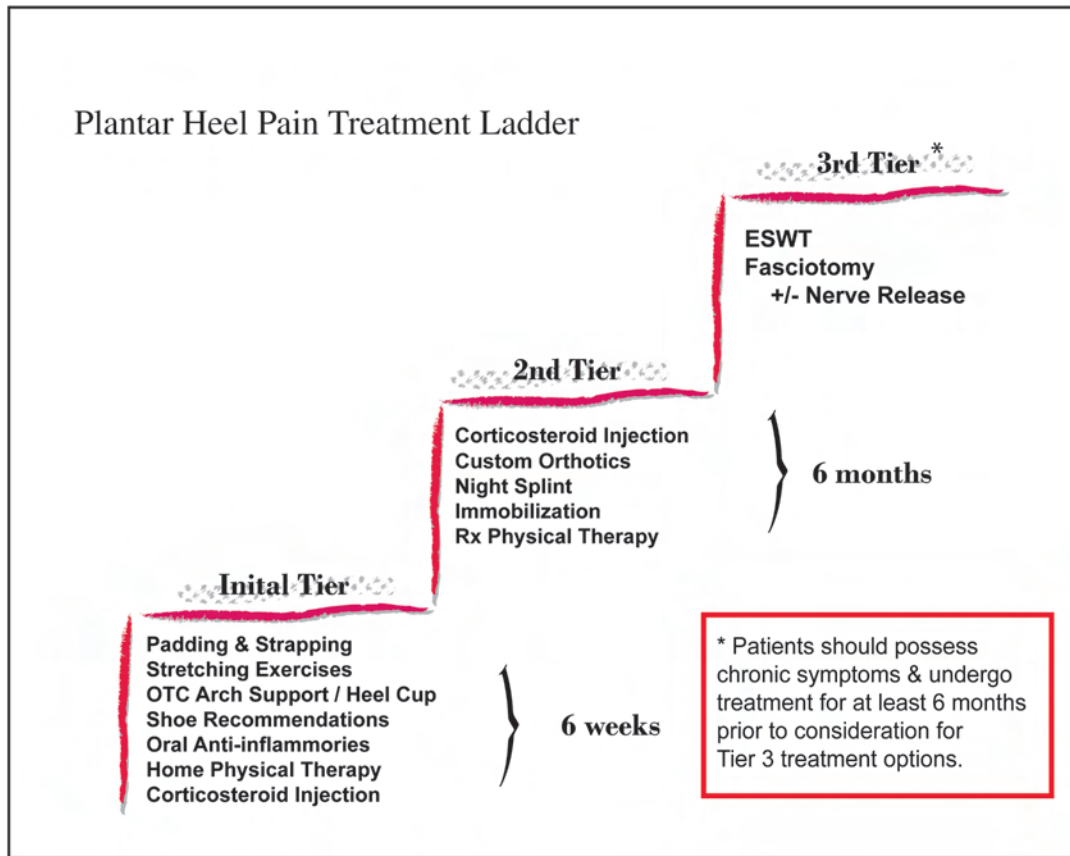


Fig. 4. The Plantar Heel Pain Treatment Ladder illustrates the stepwise approach to the ubiquitous condition of plantar heel pain. Initial treatment alternatives should be simple and cost-effective, whereas more resistant cases require more aggressive treatment. Few patients with plantar heel pain require surgical or invasive treatment therapies.

Posterior Heel Pain (Pathway 3)

The posterior heel is the second most common location of mechanically induced heel pain. Pathology in this area is categorized as (1) Achilles insertional tendinopathy or enthesopathy, and (2) Haglund’s deformity with or without retrocalcaneal bursitis (Figure 6).

Achilles enthesopathy most commonly presents with an insidious onset and frequently leads to chronic posterior heel pain and swelling (219–221). Pain is aggravated by increased activity (eg, walking,

running) and increased pressure caused by the shoe’s heel counter. A palpable prominence may be appreciated both medially and laterally to the insertion of the Achilles tendon. On physical examination, tenderness can be central or more globally located posteriorly. Other proximal pathologies of the Achilles tendon must be ruled out (222). Achilles-related tendinopathy and rupture have also been related to fluoroquinolone use (223–247). In addition, symptoms associated with retrocalcaneal bursitis may occur. Radiographic findings commonly show insertional proliferative spurring and/or erosion or intra-tendinous calcifications (Figure 6).

Initial treatment focuses on reduction of pressure to the area (eg, open-back shoes); reduction of tensile stress on the tendo Achilles with heel lifts, orthotic devices, or rocker sole shoes; topical anti-inflammatory agents; and various physical therapy modalities including stretching. Primary treatment with immobilization may be considered in particularly acute cases, although this is more commonly used if the previously described treatments are unsuccessful. Local corticosteroid injections in the Achilles tendon are not recommended (97, 248–251), although various transdermal modalities including iontophoresis may be considered. If retrocalcaneal bursitis is present, injection therapy may be used with caution to avoid intratendinous injection. Postinjection reduction of activity and/or immobilization is recommended.

EBM conclusions regarding initial or nonsurgical treatment of Achilles enthesopathy and tendinopathy reflect a Level IV level of evidence.

Resistant cases should be referred to a foot and ankle surgeon. Surgery may be indicated—eg, resection of the posterior superior

Table 1
Level of evidence and grades of recommendation

<p>Level of Evidence</p> <ul style="list-style-type: none"> – Level I: High quality prospective randomized clinical trial – Level II: Prospective comparative study – Level III: Retrospective case control study – Level IV: Expert opinion <p>Grades of Recommendation (given to various treatment options based on Level of Evidence supporting that treatment)</p> <ul style="list-style-type: none"> – Grade A: Treatment options are supported by strong evidence (consistent with Level I or II studies) – Grade B: Treatment options are supported by fair evidence (consistent with Level III or IV studies) – Grade C: Treatment options are supported by either conflicting or (Level IV studies) – Grade I: When insufficient evidence to make a recommendation

Adapted from League AC. Current concepts review: plantar fasciitis. Foot Ankle Int 29:358–366, 2008.

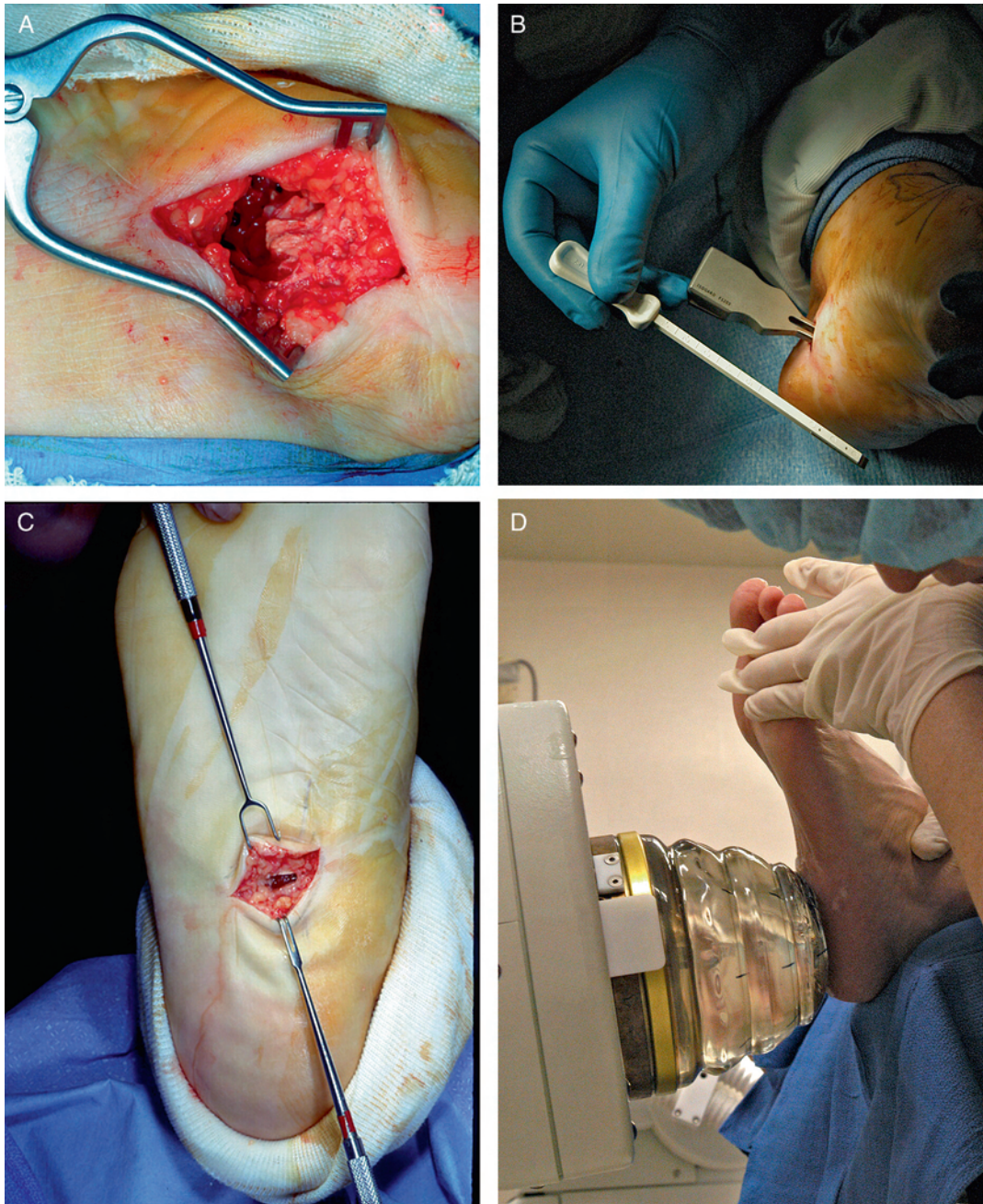

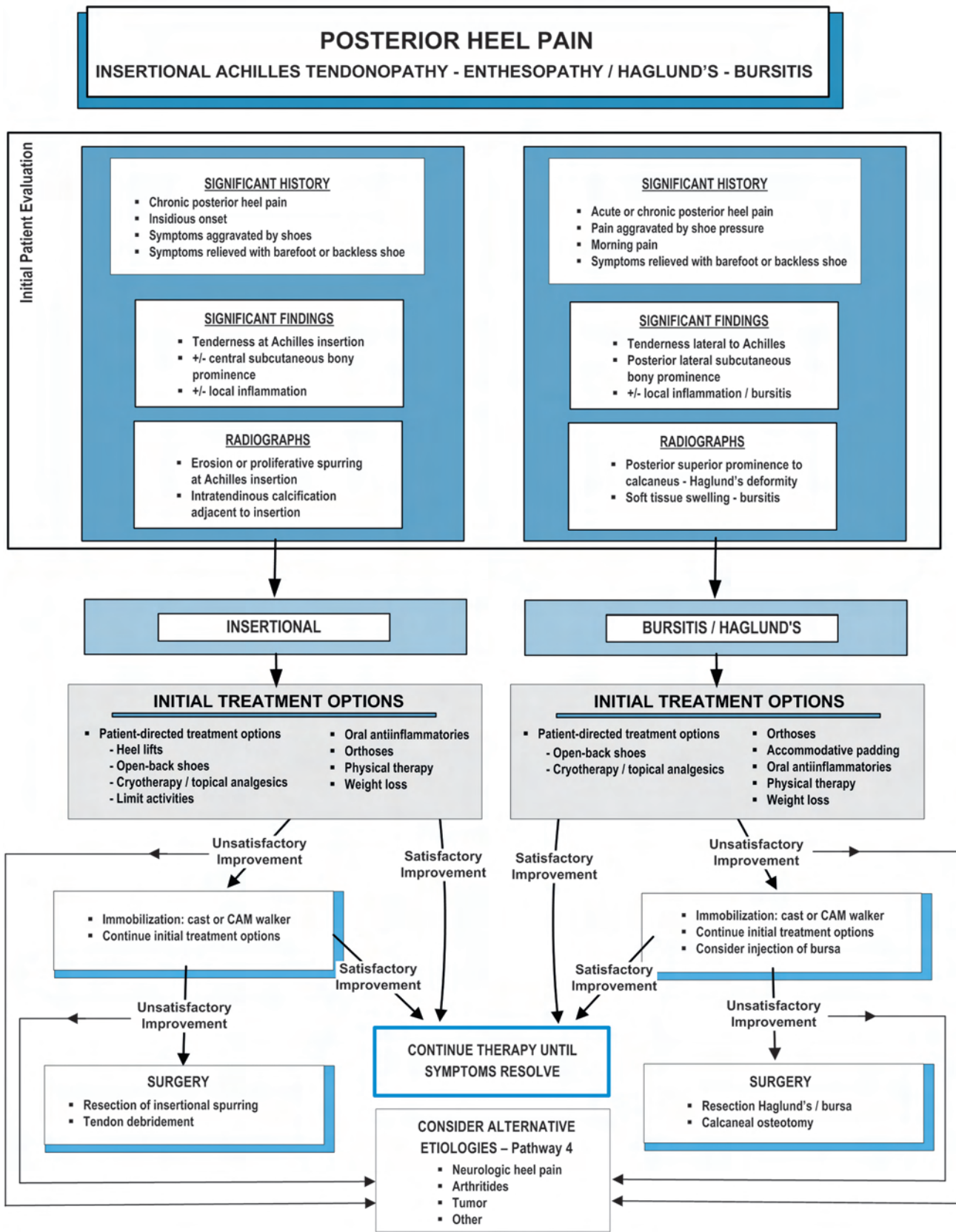
Fig. 5. Operative treatment of plantar fasciitis may include (A) open plantar fasciotomy, (B) minimally invasive plantar fasciotomy, or (C) instep plantar fasciotomy. (D) Extracorporeal shockwave therapy has become a popular alternative to traditional surgical approaches.

aspect of calcaneus, enthesophytes of the Achilles along with pathologic soft tissue (inflamed bursa, diseased tendon), or more proximal tendon debridement (222, 252–263). Various degrees of detachment with subsequent reattachment of the Achilles tendon may be needed to ensure complete resection of the spur (264). Patients should also be evaluated for equinus and need for Achilles lengthening or gastrocnemius recession (265). ESWT is another approach that has been proposed for Achilles enthesopathy and tendinopathy (266–269). To stimulate neovascular genesis, radiofrequency coblation can also be applied to the Achilles tendon in the treatment of the tendinopathy often associated with retrocalcaneal heel pain (270–272).

EBM conclusions regarding surgical treatment of Achilles enthesopathy and tendinopathy are as follows:

- Resection of the posterior superior aspect of calcaneus, enthesophytes of the Achilles along with pathologic soft tissue (inflamed bursa, diseased tendon), or more proximal tendon debridement [Grade B recommendation] (222, 252–263)
- Achilles lengthening or gastrocnemius recession [Grade I recommendation] (265)
- ESWT [Grade B recommendation] (266–269)
- Radiofrequency coblation [Grade I recommendation] (279–272)

Pathway 3



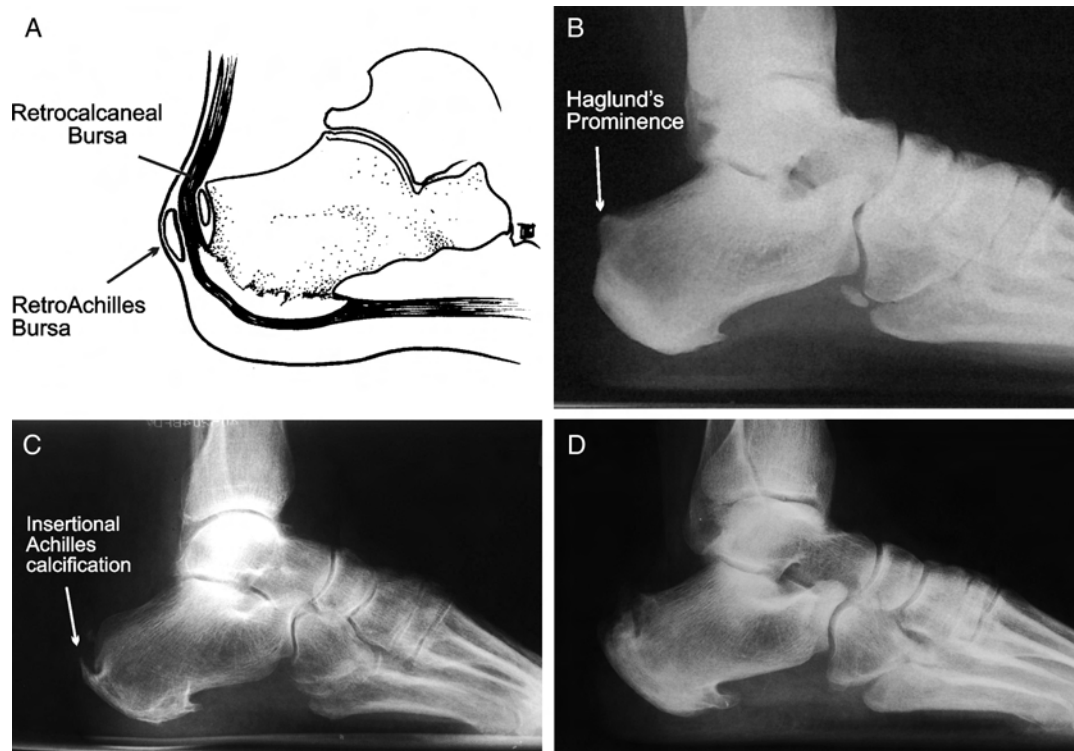


Fig. 6. Posterior heel pain is generally associated with (A) a posterior superior calcaneal bony prominence or Haglund's deformity with or without associated bursitis, which may develop (B) retrocalcaneal or retroAchilles. (C) Insertional pathology of the Achilles is common with insertional calcification and (D) at times very exuberant proliferative changes.

Haglund's deformity with or without retrocalcaneal bursitis may occur in both sexes and at any age, although 3 studies have shown that females aged 20 to 30 years are most commonly affected (222, 273–278). Symptoms include pain and inflammation that is significantly aggravated by shoe wear. Pain may be relieved with barefoot walking or use of open-heel shoes. On physical examination, there is tenderness lateral to the Achilles tendon, usually associated with a palpable posterior lateral prominence. Radiographs commonly demonstrate prominence of the posterior superior surface of the calcaneus. The degree of prominence may be quantified by documenting specific radiographic angles (221, 273, 274, 279–281).

Initial treatment—eg, open-back shoes, nonsteroidal anti-inflammatory drug (NSAID) therapy, injection therapy (with care taken not to inject the Achilles tendon)—is directed toward eliminating pressure and relieving inflammation to the symptomatic area. Physical therapy also may be helpful, particularly in recalcitrant cases.

If symptoms are not improved after an adequate period of nonoperative treatment, surgery may be considered. Resection of the prominent posterior superior aspect of the calcaneus and inflamed bursa is the indicated surgical procedure (Figure 7) (221, 273, 282–290). Although not commonly performed, calcaneal osteotomy may also be considered to correct abnormal calcaneal alignment (eg, calcaneal varus) (291–294).

EBM conclusions regarding initial or nonsurgical treatment of Haglund's deformity and retrocalcaneal bursitis are as follows:

- Open resection of the prominent posterior superior aspect of the calcaneus and inflamed bursa [Grade B recommendation] (221, 273, 282–290)
- Endoscopic calcaneoplasty [Grade I recommendation] (289, 295, 296)
- Calcaneal osteotomy [Grade C recommendation] (291–294)

Additional Etiologies of Heel Pain (Pathway 4)

Neurologic Heel Pain (Pathway 4)

Neurologic heel pain is defined as pain in the heel as a result of an entrapment or irritation of one or more of the nerves that innervate this region. Symptoms may arise in patients initially diagnosed with plantar fasciitis, and careful assessment may yield neurologically mediated pathology (32, 297, 298). Patients with a history of previous heel surgery or trauma should be highly suspect for neurologic heel pain (299, 300). The nerves or nerve branches (Figure 8) specifically considered are as follows:

- Posterior tibial (tarsal tunnel syndrome) (24, 301)
- Medial calcaneal (heel neuroma) (28–30, 33, 40–42, 299, 302, 303)
- Medial plantar (26)
- Lateral plantar, including branch to abductor digiti minimi (22, 27, 31, 39, 304–306)
- Sural, including lateral calcaneal (307, 308)

Neurologic pain in the heel or loss of sensation in the foot and/or heel can also be attributable to more proximal nerve impingement syndromes (26, 309). Patients describing pain that originates in the low back and radiates down the leg and into the foot must be assessed for radiculopathy secondary to proximal nerve root pathology. Published reports have described the double-crush syndrome, in which concomitant proximal and distal nerve entrapments may occur simultaneously (26, 310–313).

If neurologic heel pain is suspected, with presence of sensory disturbances, radiating heel pain, and other symptoms, appropriate referral for diagnostic studies and/or assessment by a specialist

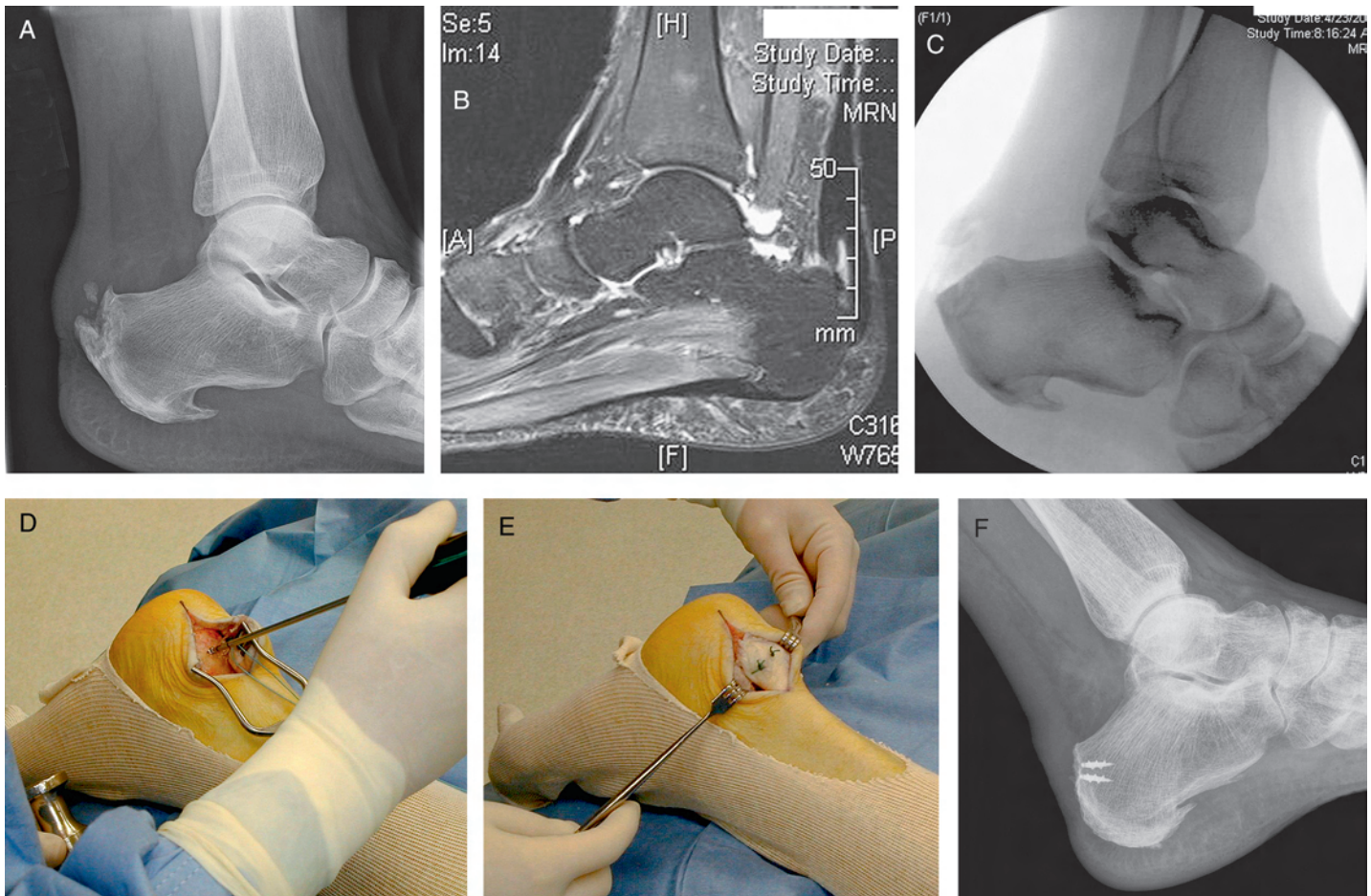


Fig. 7. (A) This radiograph reveals that the patient has both an Achilles enthesophyte and a posterior superior prominence of the calcaneus. (B) MRI shows insertional tendinopathy with a small intrasubstance tear of the Achilles tendon. (C) The surgery was performed through a posterior lateral longitudinal approach with detachment of the tendo Achilles. The enthesophyte was resected and the entire posterior superior aspect of the calcaneus was remodeled, shown here in an intraoperative fluoroscopy image. (D) Bone anchors were inserted and (E) the tendo Achilles was reattached, (F) as shown in this postoperative radiograph.

should be considered (26, 34, 297, 301, 303). Diagnostic studies may include electromyography (EMG), nerve conduction velocity (NCV) test, magnetic resonance imaging (MRI) (143, 300, 301), and pressure-specified sensory device (PSSD) test (32).

The exact prevalence of heel pain secondary to neurologic causes in the general population is unknown (30, 38, 314, 315). Obesity, venous insufficiency, trauma, and space-occupying lesions may be causative factors of nerve compression (26, 316). Most causes of neurologic heel pain are unilateral. However, bilateral cases of entrapment neuropathy causing symptoms have been reported (317). In suspected neurologic heel pain, especially in bilateral presentations, an underlying systemic disease (eg, neuropathies secondary to diabetes, vitamin deficiency, alcoholism) must be ruled out (318–327).

After consultation reports and diagnostic studies are reviewed, an accurate diagnosis and treatment protocol can be developed. The foot and ankle surgeon may manage local conditions, whereas referral to appropriate specialists may be required if the symptoms are found to originate from more proximal or lumbosacral pathology. In some instances, a combination of pathologies may occur and surgical management will require intervention at both the area of nerve entrapment and the plantar fascia (328–330).

EBM conclusions are as follows: intervention at both the area of nerve entrapment and the plantar fascia [Grade B recommendation].

Arthritides in Heel Pain (Pathway 4)

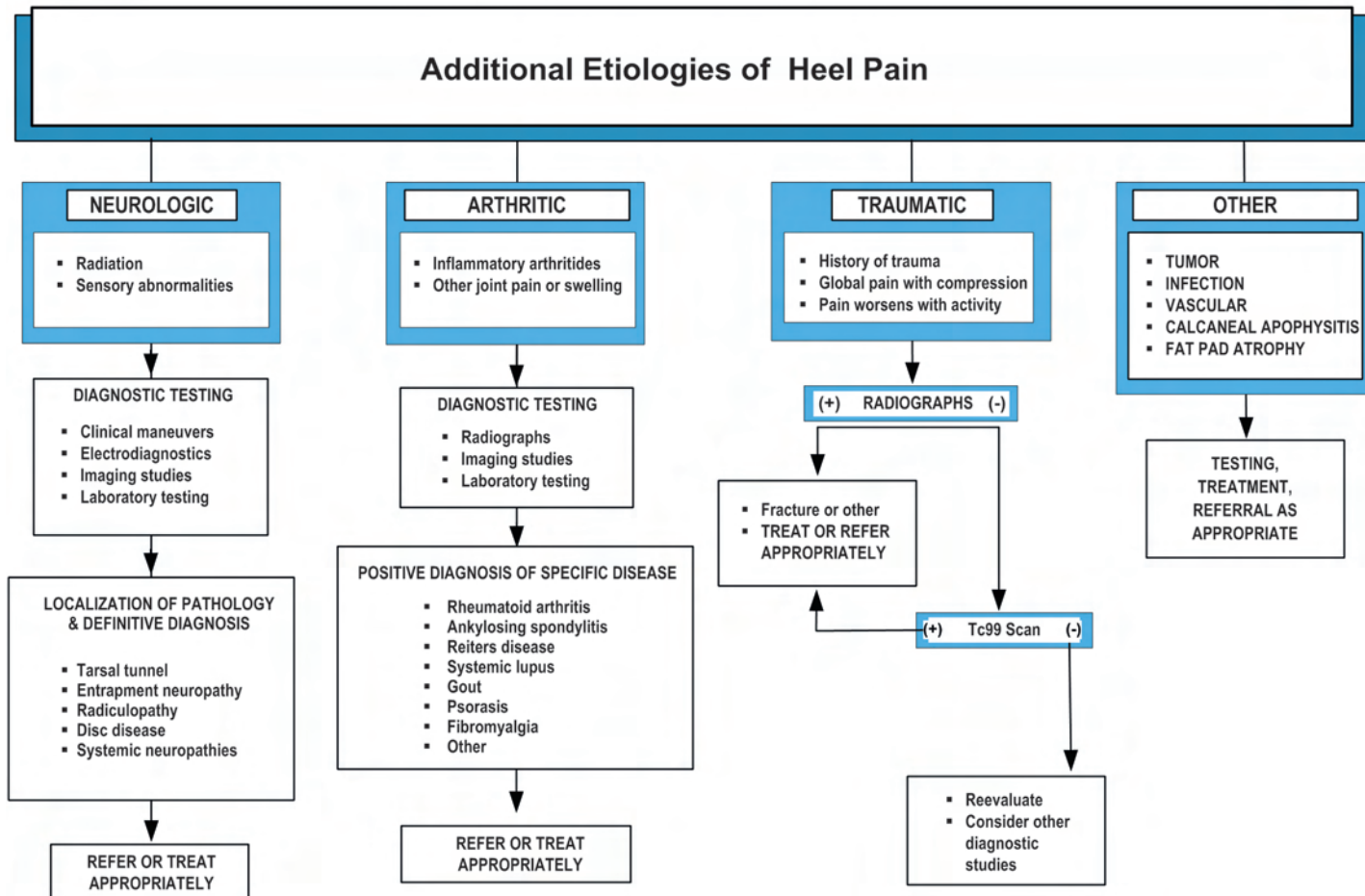
Most cases of heel pain encountered in clinical practice are likely to have a biomechanical etiology and respond to recommended therapy. In the process of taking a history and conducting a physical examination, the clinician should consider that various systemic arthritides are also capable of presentation as heel pain (Figure 9). These include the seronegative arthritides, psoriatic arthritis, Reiter's disease, diffuse idiopathic skeletal hyperostosis (DISH), rheumatoid arthritis, fibromyalgia, and gout (45, 130, 134, 135, 142, 158, 327, 331–411).

Patients with arthritides and heel pain may have other joint symptoms and should be questioned regarding concomitant arthralgias. This, in conjunction with careful radiographic evaluation and laboratory testing, may assist in determining the correct diagnosis and proper treatment for these unresponsive patients. Occasionally, scintigraphy may be useful in the diagnosis process because a pattern of joint involvement will be evidenced (412–417). Radiographs of the heel may show erosions or proliferative changes specific to one of these diseases (Figure 9). Rheumatologic consultation may be useful in determining the diagnosis and treatment.

Traumatic Heel Pain (Pathway 4)

Acute trauma to the calcaneus is the most common osseous cause of heel pain. In nearly all cases, the mechanism of injury is a fall from

Pathway 4



a height onto the heel. Intra-articular fractures involving the subtalar joint result in diffuse pain in the hindfoot that is poorly localized to the heel itself. In less severe injuries, more focal symptoms are found that correspond to the anatomic area of the fracture. These include isolated

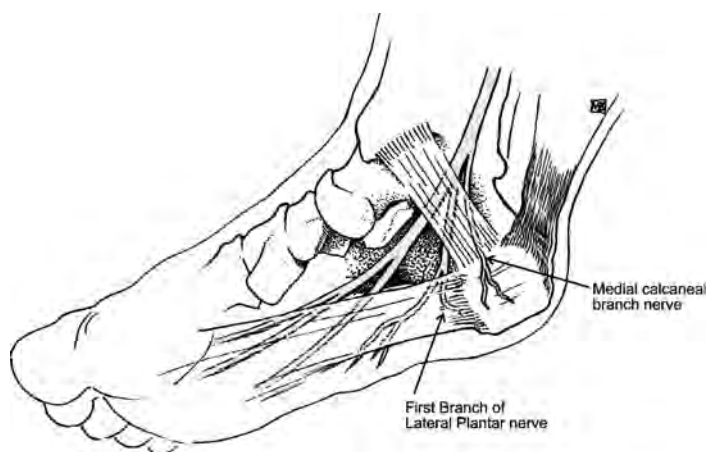


Fig. 8. In chronic neurologic heel pain, both the medial calcaneal nerve branches and the first branch of the lateral plantar nerve may be implicated.

injuries to the sustentaculum tali or the plantar calcaneal tubercles, avulsion of the posterior aspect of the tuber, or even fracture of the inferior calcaneal spur (418). Diagnosis is made by a history of trauma, focal pain upon palpation, and radiographic confirmation of the fracture. Treatment may be surgical, although many relatively minor fractures often may occur in older or high-risk individuals for whom nonsurgical management may be the most judicious course. In cases where the fracture fragments are small, nonarticular, or minimally displaced, treatment typically consists of simple immobilization.

Stress fractures of the calcaneus occur as a consequence of repetitive load to the heel (394, 402). The most common site of stress fracture is immediately posterior and inferior to the posterior facet of the subtalar joint. Although the exact mechanism is unknown, historically many patients report an antecedent increase in walking activity immediately before the onset of symptoms. The diagnosis should be entertained upon clinical suspicion and elicitation of such a history. In addition, the presence of diabetes or other endocrine abnormality should alert the clinician to possible neuropathic fracture (419–421). The physical findings include tenderness to the lateral wall of the calcaneus, immediately posterior to the facet. Swelling and warmth may be present. Pain elicited with compression of the calcaneus is highly suspicious of a stress fracture. Frequently the onset of symptoms precedes the radiographic findings, and ancillary measures can assist in early diagnosis. Technetium bone scans or MRI

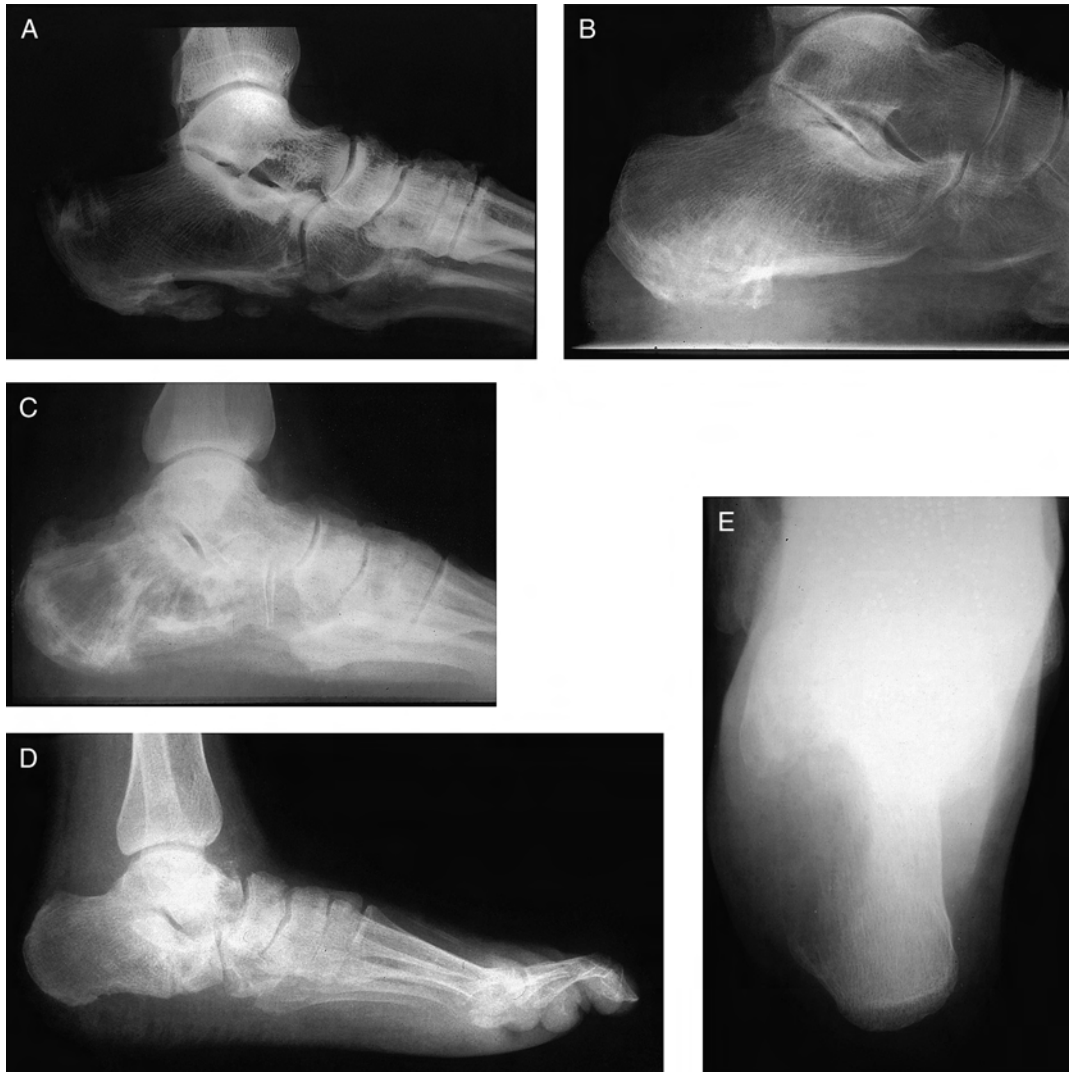

Fig. 9. As depicted in these radiographs, very diverse pathologies may be responsible for heel pain. These include (A) proliferative enthesopathies, DISH (diffuse idiopathic skeletal hyperostosis) with ossification within the plantar fascia; (B) Reiter's disease with fluffy periostitis of the inferior tuberosity; (C) Paget's disease with a "moth-eaten" ground glass bone density; (D) neuropathic fracture in a patient with diabetes; and (E) malignant bone tumor in a young male with a large lytic lesion of the lateral calcaneal wall.

scans are highly sensitive for stress fractures of the calcaneus in this setting (95, 99, 420). Radiographic features include an area of linear sclerosis corresponding to the fracture site. Treatment is conservative and involves protection and immobilization of the involved foot (133, 332, 419, 422–438). Progression to an acute fracture is uncommon.

Soft tissue trauma (eg, acute plantar fascia rupture) also can cause heel pain and may be present in patients who have negative radiographic and bone scan findings (391, 439–451). Clinical examination and appropriate diagnostic imaging can lead to establishing a diagnosis and treatment plan. Plantar fascia rupture has also been reported as a complication of heel corticosteroid injection (297, 377, 423, 432, 433, 452–455).

Other Causes of Heel Pain (Pathway 4)

Although less common, conditions such as benign and malignant tumors (297, 377, 423, 428, 454–461), infection (soft tissue and bone) (441, 443–446, 448), and vascular compromise (462) must be considered as etiologies of a patient's heel pain (Figure 9). The potential morbidity of these conditions is substantial. Proper

diagnostic testing along with consultation or referral to the appropriate specialist are paramount in these individuals.

In adolescents, calcaneal apophysitis is probably the most frequent etiology of heel pain. Palliative treatment is successful in nearly all cases (443–446, 448, 450).

References

1. Rompe JD, Furia J, Weil L, Maffulli N. Shock wave therapy for chronic plantar fasciopathy. *Br Med Bull* 81–82:183–208, 2007.
2. Lemont H, Ammirati KM, Usen N. Plantar fasciitis: a degenerative process (fasciosis) without inflammation. *J Am Podiatr Med Assoc* 93:234–237, 2003.
3. Hammer WI. The effect of mechanical load on degenerated soft tissue. *J Body Mov Ther* 12:246–256, 2008.
4. Bergmann JN. History and mechanical control of heel spur pain. *Clin Podiatr Med Surg* 7:243–259, 1990.
5. Contampasis JP. Surgical treatment of calcaneal spurs. *J Am Podiatr Assoc* 64:987–999, 1974.
6. McCarthy DJ, Gorecki GE. The anatomical basis of inferior calcaneal lesions. *J Am Podiatr Assoc* 69:527–536, 1979.
7. Mitchell IR, Meyer C, Krueger WA. Deep fascia of the foot. Anatomical and clinical considerations. *J Am Podiatr Med Assoc* 81:373–378, 1991.
8. Nack JD, Phillips RD. Shock absorption. *Clin Podiatr Med Surg* 7:391–397, 1990.
9. Root M, Weed J, Orien W. *Normal and Abnormal Function of the Foot, vol. II.* 326–332, Clinical Biomechanics Corp, Los Angeles, 1977.

10. Fuller EA. The windlass mechanism of the foot. A mechanical model to explain pathology. *J Am Podiatr Med Assoc* 90:35–46, 2000.
11. Kogler GF, Solomonidis SE, Paul JP. Biomechanics of longitudinal arch support mechanisms in foot orthoses and their effect on plantar aponeurosis strain. *Clin Biomech (Bristol, Avon)* 11:243–252, 1996.
12. Messier SP. Obesity and osteoarthritis: disease genesis and nonpharmacologic weight management. *Rheum Dis Clin North Am* 34:713–729, 2008.
13. Menz HB, Zammit GV, Landorf KB, Munteanu SE. Plantar calcaneal spurs in older people: longitudinal traction or vertical compression? *J Foot Ankle Res* 1:7, 2008.
14. Hill JJ, Cutting PJ. Heel pain and body weight. *Foot Ankle* 9:254–256, 1989.
15. Hills AP, Hennig EM, McDonald M, Bar-Or O. Plantar pressure differences between obese and non-obese adults: a biomechanical analysis. *Int J Obes Relat Metab Disord* 25:1674–1679, 2001.
16. Gill LH. Plantar fasciitis: diagnosis and conservative management. *J Am Acad Orthop Surg* 5:109–117, 1997.
17. Irving DB, Cook JL, Young MA, Menz HB. Obesity and pronated foot type may increase the risk of chronic plantar heel pain: a matched case-control study. *BMC Musculoskelet Disord* 8:41, 2007.
18. Wearing SC, Hennig EM, Byrne NM, Steele JR, Hills AP. Musculoskeletal disorders associated with obesity: a biomechanical perspective. *Obes Rev* 7:239–250, 2006.
19. Riddle DL, Pulisic M, Pidcoe P, Johnson RE. Risk factors for plantar fasciitis: a matched case-control study. *J Bone Joint Surg Am* 85-A:872–877, 2003.
20. Irving DB, Cook JL, Menz HB. Factors associated with chronic plantar heel pain: a systematic review. *J Sci Med Sport* 9:11–22, 2006. discussion 23–14.
21. Bolgia LA, Malone TR. Plantar fasciitis and the windlass mechanism: a biomechanical link to clinical practice. *J Athl Train* 39:77–82, 2004.
22. Goecker RM, Banks AS. Analysis of release of the first branch of the lateral plantar nerve. *J Am Podiatr Med Assoc* 90:281–286, 2000.
23. Louisia S, Masquelet AC. The medial and inferior calcaneal nerves: an anatomic study. *Surg Radiol Anat* 21:169–173, 1999.
24. Hendrix CL, Jolly GP, Garbalosa JC, Blume P, DosRemedios E. Entrapment neuropathy: the etiology of intractable chronic heel pain syndrome. *J Foot Ankle Surg* 37:273–279, 1998.
25. Johnston MR. Nerve entrapment causing heel pain. *Clin Podiatr Med Surg* 11:617–624, 1994.
26. Schon LC, Glennon TP, Baxter DE. Heel pain syndrome: electrodiagnostic support for nerve entrapment. *Foot Ankle* 14:129–135, 1993.
27. Baxter DE, Pfeiffer GB. Treatment of chronic heel pain by surgical release of the first branch of the lateral plantar nerve. *Clin Orthop Relat Res* 279:229–236, 1992.
28. Davidson MR, Copoloff JA. Neuromas of the heel. *Clin Podiatr Med Surg* 7:271–288, 1990.
29. Dida BC, Horsefall AU. Medial calcaneal nerve: an anatomical study. *J Am Podiatr Med Assoc* 80:115–119, 1990.
30. Henricson AS, Westlin NE. Chronic calcaneal pain in athletes: entrapment of the calcaneal nerve? *Am J Sports Med* 12:152–154, 1984.
31. Przylucki H, Jones CL. Entrapment neuropathy of muscle branch of lateral plantar nerve: a cause of heel pain. *J Am Podiatry Assoc* 71:119–124, 1981.
32. Dellon AL. Technique for determining when plantar heel pain can be neural in origin. *Microsurgery* 28:403–406, 2008.
33. Diers DJ. Medial calcaneal nerve entrapment as a cause for chronic heel pain. *Physiother Theory Pract* 24:291–298, 2008.
34. Saggini R, Bellomo RG, Affaitati G, Lapenna D, Giamberardino MA. Sensory and biomechanical characterization of two painful syndromes in the heel. *J Pain* 8:215–222, 2007.
35. Jolly GP, Zgonis T, Hendrix CL. Neurogenic heel pain. *Clin Podiatr Med Surg* 22:101–113, 2005. vii.
36. Oztuna V, Ozge A, Eskandari MM, Colak M, Golpinar A, Kuyurtar F. Nerve entrapment in painful heel syndrome. *Foot Ankle Int* 23:208–211, 2002.
37. Pfeiffer GB. Plantar heel pain. *Instr Course Lect* 50:521–531, 2001.
38. Kenzora JE. The painful heel syndrome: an entrapment neuropathy. *Bull Hosp Joint Dis Orthop Inst* 47:178–189, 1987.
39. Toomey EP. Plantar heel pain. *Foot Ankle Clin* 14:229–245, 2009.
40. Plotkin D, Patel D, Roberto T. Heel neuroma: a case study. *J Foot Ankle Surg* 48:376–379, 2009.
41. Liden B, Simmons M, Landsman AS. A retrospective analysis of 22 patients treated with percutaneous radiofrequency nerve ablation for prolonged moderate to severe heel pain associated with plantar fasciitis. *J Foot Ankle Surg* 48:642–647, 2009.
42. Cione JA, Cozzarelli J, Mullin CJ. A retrospective study of radiofrequency thermal lesioning for the treatment of neuritis of the medial calcaneal nerve and its terminal branches in chronic heel pain. *J Foot Ankle Surg* 48:142–147, 2009.
43. Sinnavee F, Vandeputte G. Clinical outcome of surgical intervention for recalcitrant infero-medial heel pain. *Acta Orthop Belg* 74:483–488, 2008.
44. Shikoff MD, Figura MA, Postar SE. A retrospective study of 195 patients with heel pain. *J Am Podiatr Med Assoc* 76:71–75, 1986.
45. Williams PL. The painful heel. *Br J Hosp Med* 38:562–563, 1987.
46. Rano JA, Fallat LM, Savoy-Moore RT. Correlation of heel pain with body mass index and other characteristics of heel pain. *J Foot Ankle Surg* 40:351–356, 2001.
47. Ozdemir H, Soyuncu Y, Ozgorgen M, Dabak K. Effects of changes in heel fat pad thickness and elasticity on heel pain. *J Am Podiatr Med Assoc* 94:47–52, 2004.
48. Osborne HR, Breidahl WH, Allison GT. Critical differences in lateral X-rays with and without a diagnosis of plantar fasciitis. *J Sci Med Sport* 9:231–237, 2006.
49. Falsetti P, Frediani B, Acciai C, Baldi F, Filippou G, Marcolongo R. Heel fat pad involvement in rheumatoid arthritis and in spondyloarthropathies: an ultrasonographic study. *Scand J Rheumatol* 33:327–331, 2004.
50. Jahss MH, Kummer F, Michelson JD. Investigations into the fat pads of the sole of the foot: heel pressure studies. *Foot Ankle* 13:227–232, 1992.
51. Tsai WC, Wang CL, Hsu TC, Hsieh FJ, Tang FT. The mechanical properties of the heel pad in unilateral plantar heel pain syndrome. *Foot Ankle Int* 20:663–668, 1999.
52. Shama SS, Kominsky SJ, Lemont H. Prevalence of non-painful heel spur and its relation to postural foot position. *J Am Podiatry Assoc* 73:122–123, 1983.
53. Kelly A, Wainwright A, Winson I. Spur formation and heel pain. *Clin Orthop Relat Res* 319:330, 1995.
54. Lapidus PW, Guidotti FP. Painful heel: report of 323 patients with 364 painful heels. *Clin Orthop Relat Res* 39:178–186, 1965.
55. Landorf KB, Radford JA, Keenan AM, Redmond AC. Effectiveness of low-Dye taping for the short-term management of plantar fasciitis. *J Am Podiatr Med Assoc* 95:525–530, 2005.
56. Landorf KB, Keenan AM, Herbert RD. Effectiveness of different types of foot orthoses for the treatment of plantar fasciitis. *J Am Podiatr Med Assoc* 94:542–549, 2004.
57. Landorf KB, Keenan AM, Herbert RD. Effectiveness of foot orthoses to treat plantar fasciitis: a randomized trial. *Arch Intern Med* 166:1305–1310, 2006.
58. Pfeiffer GB, Bacchetti P, Deland J, Lewis A, Anderson R, Davis W, Alvarez R, Brodsky J, Cooper P, Frey C, Herrick R, Myerson M, Sammarco J, Janecki C, Ross S, Bowman M, Smith R. Comparison of custom and prefabricated orthoses in the initial treatment of proximal plantar fasciitis. *Foot Ankle Int* 20:214–221, 1999.
59. Roos E, Engstrom M, Soderberg B. Foot orthoses for the treatment of plantar fasciitis. *Foot Ankle Int* 27:606–611, 2006.
60. Caselli MA, Clark N, Lazarus S, Velez Z, Venegas L. Evaluation of magnetic foil and PPT insoles in the treatment of heel pain. *J Am Podiatr Med Assoc* 87:11–16, 1997.
61. Stuber K, Kristmanson K. Conservative therapy for plantar fasciitis: a narrative review of randomized controlled trials. *JCCA J Can Chiropr Assoc* 50:118–133, 2006.
62. Filippou DK, Kalliakmanis A, Triga A, Rizos S, Grigoriadis E, Shipkov CD. Sport related plantar fasciitis. Current diagnostic and therapeutic advances. *Folia Med (Plovdiv)* 46:56–60, 2004.
63. Donley BG, Moore T, Sferra J, Gozdanovic J, Smith R. The efficacy of oral nonsteroidal anti-inflammatory medication (NSAID) in the treatment of plantar fasciitis: a randomized, prospective, placebo-controlled study. *Foot Ankle Int* 28:20–23, 2007.
64. Pribut SM. Current approaches to the management of plantar heel pain syndrome, including the role of injectable corticosteroids. *J Am Podiatr Med Assoc* 97:68–74, 2007.
65. Barrett SJ, O'Malley R. Plantar fasciitis and other causes of heel pain. *Am Fam Physician* 59:2200–2206, 1999.
66. Tatli YZ, Kapasi S. The real risks of steroid injection for plantar fasciitis, with a review of conservative therapies. *Curr Rev Musculoskelet Med* 2:3–9, 2009.
67. Crawford F, Atkins D, Young P, Edwards J. Steroid injection for heel pain: evidence of short-term effectiveness. A randomized controlled trial. *Rheumatology (Oxford)* 38:974–977, 1999.
68. Kalaci A, Cakici H, Hapa O, Yanat AN, Dogramaci Y, Sevinç TT. Treatment of plantar fasciitis using four different local injection modalities: a randomized prospective clinical trial. *J Am Podiatr Med Assoc* 99:108–113, 2009.
69. DiGiovanni BF, Nawoczenski DA, Lintal ME, Moore EA, Murray JC, Wilding GE, Baumhauer JF. Tissue-specific plantar fascia-stretching exercise enhances outcomes in patients with chronic heel pain. A prospective, randomized study. *J Bone Joint Surg Am* 85-A:1270–1277, 2003.
70. DiGiovanni BF, Nawoczenski DA, Malay DP, Graci PA, Williams TT, Wilding GE, Baumhauer JF. Plantar fascia-specific stretching exercise improves outcomes in patients with chronic plantar fasciitis. A prospective clinical trial with two-year follow-up. *J Bone Joint Surg Am* 88:1775–1781, 2006.
71. Spears IR, Miller-Young JE, Waters M, Rome K. The effect of loading conditions on stress in the barefooted heel pad. *Med Sci Sports Exerc* 37:1030–1036, 2005.
72. Burnfield JM, Few CD, Mohamed OS, Perry J. The influence of walking speed and footwear on plantar pressures in older adults. *Clin Biomech (Bristol, Avon)* 19:78–84, 2004.
73. Bedinghaus JM, Niedfeldt MW. Over-the-counter foot remedies. *Am Fam Physician* 64:791–796, 2001.
74. League AC. Current concepts review: plantar fasciitis. *Foot Ankle Int* 29:358–366, 2008.
75. Rome K, Gray J, Stewart F, Hannant SC, Callaghan D, Hubble J. Evaluating the clinical effectiveness and cost-effectiveness of foot orthoses in the treatment of plantar heel pain: a feasibility study. *J Am Podiatr Med Assoc* 94:229–238, 2004.
76. Lee SY, McKeon P, Hertel J. Does the use of orthoses improve self-reported pain and function measures in patients with plantar fasciitis? A meta-analysis. *Phys Ther Sport* 10:12–18, 2009.
77. Martin JE, Hosch JC, Goforth WP, Murff RT, Lynch DM, Odom RD. Mechanical treatment of plantar fasciitis. A prospective study. *J Am Podiatr Med Assoc* 91:55–62, 2001.
78. Campbell JW, Inman VT. Treatment of plantar fasciitis and calcaneal spurs with the UC-BL shoe insert. *Clin Orthop Relat Res* 103:57–62, 1974.
79. Crawford F, Atkins D, Edwards J. Interventions for treating plantar heel pain (Cochrane review). *Cochrane Database Syst Rev* 3. CD000416.

80. Huang HH, Qureshi AA, Biundo JJ. Sports and other soft tissue injuries, tendinitis, bursitis, and occupation-related syndromes. *Curr Opin Rheumatol* 12:150–154, 2000.
81. Powell M, Post WR, Keener J, Wearden S. Effective treatment of chronic plantar fasciitis with dorsiflexion night splints: a crossover prospective randomized outcome study. *Foot Ankle Int* 19:10–18, 1998.
82. Weise J. Plantar fasciitis, posterior night splints and activity during recovery. *Am Fam Physician* 53:1996, 1994.
83. Ryan J. Use of posterior night splints in the treatment of plantar fasciitis. *Am Fam Physician* 52:891–898, 901–892, 1995.
84. Wapner KL, Sharkey PF. The use of night splints for treatment of recalcitrant plantar fasciitis. *Foot Ankle Int* 12:135–137, 1991.
85. Neufeld SK, Cerrato R. Plantar fasciitis: evaluation and treatment. *J Am Acad Orthop Surg* 16:338–346, 2008.
86. Cole C, Seto C, Gazewood J. Plantar fasciitis: evidence-based review of diagnosis and therapy. *Am Fam Physician* 72:2237–2242, 2005.
87. Crawford F, Thomson C. Interventions for treating plantar heel pain. *Cochrane Database Syst Rev* 3:CD000416, 2003.
88. Barry LD, Barry AN, Chen Y. A retrospective study of standing gastrocnemius-soleus stretching versus night splinting in the treatment of plantar fasciitis. *J Foot Ankle Surg* 41:221–227, 2002.
89. Young CC, Rutherford DS, Niedfeldt MW. Treatment of plantar fasciitis. *Am Fam Physician* 63:467–474, 477–468, 2001.
90. Zamorski M. Plantar fasciitis, posterior night splints and activity during recovery. *Am Fam Physician* 53:1993; author reply 1993–1994, 1996.
91. Little RB. Plantar fasciitis, posterior night splints and activity during recovery. *Am Fam Physician* 53:1993; author reply 1993–1994, 1996.
92. Probe RA, Baca M, Adams R, Preece C. Night splint treatment for plantar fasciitis. A prospective randomized study. *Clin Orthop Relat Res* 368:190–195, 1999.
93. Batt ME, Tanji JL, Skattum N. Plantar fasciitis: a prospective randomized clinical trial of the tension night splint. *Clin J Sport Med* 6:158–162, 1996.
94. Beals TC, Pomeroy GC, Manoli A. Posterior tendon insufficiency: diagnosis and treatment. *J Am Acad Orthop Surg* 7:112–118, 1999.
95. Acevedo JL, Beskin JL. Complications of plantar fascia rupture associated with corticosteroid injection. *Foot Ankle Int* 19:91–97, 1998.
96. Plantar fasciitis. Repeated corticosteroid injections are safe. *Can Fam Physician* 44:45, 51, 1998.
97. Van Wyngarden TM. The painful foot. Part II: Common rearfoot deformities. *Am Fam Physician* 55:2207–2212, 1997.
98. Cunnane G, Brophy DP, Gibney RG, FitzGerald O. Diagnosis and treatment of heel pain in chronic inflammatory arthritis using ultrasound. *Semin Arthritis Rheum* 25:383–389, 1996.
99. Sellman JR. Plantar fascia rupture associated with corticosteroid injection. *Foot Ankle Int* 15:376–381, 1994.
100. Sorrentino F, Iovane A, Vetro A, Vaccari A, Mantia R, Midiri M. Role of high-resolution ultrasound in guiding treatment of idiopathic plantar fasciitis with minimally invasive techniques. *Radiol Med* 113:486–495, 2008.
101. Lee TG, Ahmad TS. Intralesional autologous blood injection compared to corticosteroid injection for treatment of chronic plantar fasciitis. A prospective, randomized, controlled trial. *Foot Ankle Int* 28:984–990, 2007.
102. Kiter E, Celikbas E, Akkaya S, Demirkan F, Kilic BA. Comparison of injection modalities in the treatment of plantar heel pain: a randomized controlled trial. *J Am Podiatr Med Assoc* 96:293–296, 2006.
103. Buccilli TA Jr, Hall HR, Solmen JD. Sterile abscess formation following a corticosteroid injection for the treatment of plantar fasciitis. *J Foot Ankle Surg* 44:466–468, 2005.
104. Porter MD, Shadbolt B. Intralesional corticosteroid injection versus extracorporeal shock wave therapy for plantar fasciopathy. *Clin J Sport Med* 15:119–124, 2005.
105. Tallia AF, Cardone DA. Diagnostic and therapeutic injection of the ankle and foot. *Am Fam Physician* 68:1356–1362, 2003.
106. Kane D, Greaney T, Shanahan M, Duffy G, Bresnihan B, Gibney R, FitzGerald O. The role of ultrasonography in the diagnosis and management of idiopathic plantar fasciitis. *Rheumatology (Oxford)* 40:1002–1008, 2001.
107. Evans A. Podiatric medical applications of posterior night stretch splinting. *J Am Podiatr Med Assoc* 91:356–360, 2001.
108. Quinn M, Gough A. Ultrasound guided injection of plantar fasciitis. *Ann Rheum Dis* 57:749–750, 1998.
109. Miller RA, Torres J, McGuire M. Efficacy of first-time steroid injection for painful heel syndrome. *Foot Ankle Int* 16:610–612, 1995.
110. Seyler TM, Smith BP, Marker DR, Ma J, Shen J, Smith TL, Mont MA, Kolaski K, Koman LA. Botulinum neurotoxin as a therapeutic modality in orthopaedic surgery: more than twenty years of experience. *J Bone Joint Surg Am* 90(Suppl 4):133–145, 2008.
111. Jeynes LC, Gauci CA. Evidence for the use of botulinum toxin in the chronic pain setting—a review of the literature. *Pain Pract* 8:269–276, 2008.
112. Placzek R, Holscher A, Deuretzbacher G, Meiss L, Perka C. [Treatment of chronic plantar fasciitis with botulinum toxin A—an open pilot study on 25 patients with a 14-week-follow-up.]. *Z Orthop Ihre Grenzgeb* 144:405–409, 2006. German.
113. Logan LR, Klamar K, Leon J, Fedoriv W. Autologous blood injection and botulinum toxin for resistant plantar fasciitis accompanied by spasticity. *Am J Phys Med Rehabil* 85:699–703, 2006.
114. Placzek R, Deuretzbacher G, Meiss AL. Treatment of chronic plantar fasciitis with Botulinum toxin A: preliminary clinical results. *Clin J Pain* 22:190–192, 2006.
115. Placzek R, Deuretzbacher G, Buttgerit F, Meiss AL. Treatment of chronic plantar fasciitis with botulinum toxin A: an open case series with a 1 year follow up. *Ann Rheum Dis* 64:1659–1661, 2005.
116. Babcock MS, Foster L, Pasquina P, Jabbari B. Treatment of pain attributed to plantar fasciitis with botulinum toxin a: a short-term, randomized, placebo-controlled, double-blind study. *Am J Phys Med Rehabil* 84:649–654, 2005.
117. [Botulinum toxin A—therapy option in cases of chronic plantar fasciitis?—an open treatment attempt with 9 patients and a one year observation period.]. *Z Orthop Ihre Grenzgeb* 143:145–148, 2005.
118. Cleland JA, Abbott JH, Kidd MO, Stockwell S, Cheney S, Gerrard DF, Flynn TW. Manual physical therapy and exercise versus electrophysical agents and exercise in the management of plantar heel pain: a multicenter randomized clinical trial. *J Orthop Sports Phys Ther* 39:573–585, 2009.
119. Tisdell CL, Harper MC. Chronic plantar heel pain: treatment with a short leg walking cast. *Foot Ankle Int* 17:41–42, 1996.
120. Gill LH, Kiezbak GM. Outcome of nonsurgical treatment for plantar fasciitis. *Foot Ankle Int* 17:527–532, 1996.
121. Kavros SJ. The efficacy of a pneumatic compression device in the treatment of plantar fasciitis. *J Appl Biomech* 21:404–413, 2005.
122. Sadat-Ali M. Plantar fasciitis/calcaneal spur among security forces personnel. *Mil Med* 163:56–57, 1998.
123. Frey C, Zamora J. The effects of obesity on orthopaedic foot and ankle pathology. *Foot Ankle Int* 28:996–999, 2007.
124. Karr SD. Subcalcaneal heel pain. *Orthop Clin North Am* 25:161–175, 1994.
125. Lynch DM, Goforth WP, Martin JE, Odom RD, Preece CK, Kotter MW. Conservative treatment of plantar fasciitis. A prospective study. *J Am Podiatr Med Assoc* 88:375–380, 1998.
126. McBryde AM. Plantar fasciitis. *Instr Course Lect* 33:278–282, 1984.
127. Meltzer EF. A rational approach to the management of heel pain. A protocol proposal. *J Am Podiatr Med Assoc* 79:89–92, 1989.
128. Quaschnick MS. The diagnosis and management of plantar fasciitis. *Nurse Pract* 21:50–54, 60–53, quiz 64–55, 1996.
129. Kinley S, Frascione S, Calderone D, Wertheimer SJ, Squire MA, Wiseman FA. Endoscopic plantar fasciotomy versus traditional heel spur surgery: a prospective study. *J Foot Ankle Surg* 32:595–603, 1993.
130. Olivieri I, Barozzi L, Padula A. Enthesiopathy: clinical manifestations, imaging and treatment. *Baillieres Clin Rheumatol* 12:665–681, 1998.
131. Ott H, Van Linthoudt D. Heel pain in sarcoidosis—is sarcoid a cause of spondylarthropathy? *Br J Rheumatol* 26:468, 1987.
132. Pavlica L, Mitrovic D, Mladenovic V, Popovic M, Krstic S, Anđelkovic Z. [Reiter's syndrome—analysis of 187 patients.]. *Vojnosanit Pregl* 54:437–446, 1997. Serbian.
133. Perrot S, Mortier E, Renoux M, Job-Deslandre C, Menkes CJ. Monostotic Paget's disease involving the calcaneus. Diagnostic and therapeutic problems. Two case-reports. *Rev Rhum Engl Ed* 62:45–47, 1995.
134. Resnick D, Feingold ML, Curd J, Niwayama G, Goergen TG. Calcaneal abnormalities in articular disorders. Rheumatoid arthritis, ankylosing spondylitis, psoriatic arthritis and Reiter's syndrome. *Radiology* 125:355–366, 1977.
135. Resnick D, Niwayama G. Rheumatoid arthritis and the seronegative spondyloarthropathies: radiographic and pathologic changes. In *Diagnosis of Bone and Joint Disorders*, ed 3, pp 807–865, edited by D Resnick, WB Saunders, Philadelphia, 1995.
136. Shaw RA, Holt PA, Stevens MB. Heel pain in sarcoidosis. *Ann Intern Med* 109:675–677, 1988.
137. Geppert MJ, Mizel MS. Management of heel pain in the inflammatory arthritides. *Clin Orthop Relat Res* 349:93–99, 1998.
138. Campbell P, Lawton JO. Heel pain: diagnosis and management. *Br J Hosp Med* 52:380–385, 1994.
139. Dailey JM. Differential diagnosis and treatment of heel pain. *Clin Podiatr Med Surg* 8:153–166, 1991.
140. Alvarez-Nemegyei J, Canoso JJ. Heel pain: diagnosis and treatment, step by step. *Cleve Clin J Med* 73:465–471, 2006.
141. Aldridge T. Diagnosing heel pain in adults. *Am Fam Physician* 70:332–338, 2004.
142. Gerster JC, Vischer TL, Bennani A, Fallet GH. The painful heel. Comparative study in rheumatoid arthritis, ankylosing spondylitis, Reiter's syndrome, and generalized osteoarthritis. *Ann Rheum Dis* 36:343–348, 1977.
143. O'Malley MJ, Page A, Cook R. Endoscopic plantar fasciotomy for chronic heel pain. *Foot Ankle Int* 21:505–510, 2000.
144. Zimmerman BJ, Cardinal MD, Cragel MD, Goel AR, Lane JW, Schramm KA. Comparison of three types of postoperative management for endoscopic plantar fasciotomy. A retrospective study. *J Am Podiatr Med Assoc* 90:247–251, 2000.
145. Fishco WD, Goecker RM, Schwartz RI. The instep plantar fasciotomy for chronic plantar fasciitis. A retrospective review. *J Am Podiatr Med Assoc* 90:66–69, 2000.
146. Benton-Weil W, Borrelli AH, Weil LS. Percutaneous plantar fasciotomy: a minimally invasive procedure for recalcitrant plantar fasciitis. *J Foot Ankle Surg* 37:269–272, 1998.
147. Stone PA, Davies JL. Retrospective review of endoscopic plantar fasciotomy—1992 through 1994. *J Am Podiatr Med Assoc* 86:414–420, 1996.
148. Amarnek DL. The medial instep plantar fasciotomy. *J Foot Ankle Surg* 35:182–183, 1996.
149. Perelman GK, Figura MA, Sandberg NS. The medial instep plantar fasciotomy. *J Foot Ankle Surg* 34:447–457, 1995. discussion 509–510.

150. Barrett SL, Day SV, Pignetti TT, Robinson LB. Endoscopic plantar fasciotomy: a multi-surgeon prospective analysis of 652 cases. *J Foot Ankle Surg* 34:400–406, 1995.
151. Tomczak RL, Haverstock BD. A retrospective comparison of endoscopic plantar fasciotomy to open plantar fasciotomy with heel spur resection for chronic plantar fasciitis/heel spur syndrome. *J Foot Ankle Surg* 34:305–311, 1995.
152. Barrett SL. Endoscopic plantar fasciotomy. *Clin Podiatr Med Surg* 11:469–481, 1994.
153. Wander DS. Endoscopic plantar fasciotomy versus traditional heel spur surgery. *J Foot Ankle Surg* 33:322, 1994.
154. Barrett SL, Day SV. Endoscopic plantar fasciotomy vs. traditional heel spur surgery. *J Foot Ankle Surg* 33:214–216, 1994.
155. Ko JY, Wang JW, Wan YL, Chen WJ. Multiple schwannomas of the foot: report of a case. *J Formos Med Assoc* 92:845–847, 1993.
156. Daly PJ, Kitaoka HB, Chao EY. Plantar fasciotomy for intractable plantar fasciitis: clinical results and biomechanical evaluation. *Foot Ankle* 13:188–195, 1992.
157. Barrett SL, Day SV. Endoscopic plantar fasciotomy for chronic plantar fasciitis/heel spur syndrome: surgical technique—early clinical results. *J Foot Surg* 30:568–570, 1991.
158. Lafforgue P, Siles S, Daumen-Legre V, Acquaviva PC. An unexpected, benign cause of increased muscular uptake at bone scintigraphy. *Clin Exp Rheumatol* 12:309–311, 1994.
159. Lester DK, Buchanan JR. Surgical treatment of plantar fasciitis. *Clin Orthop Relat Res* 186:202–204, 1984.
160. Lewis G, Gatti A, Barry LD, Greenberg PM, Levenson M. The plantar approach to heel surgery: a retrospective study. *J Foot Surg* 30:542–546, 1991.
161. Ogilvie-Harris DJ, Lobo J. Endoscopic plantar fascia release. *Arthroscopy* 16:290–298, 2000.
162. Snider MP, Clancy WG, McBeath AA. Plantar fascia release for chronic plantar fasciitis in runners. *Am J Sports Med* 11:215–219, 1983.
163. Stone PA, McClure LP. Retrospective review of endoscopic plantar fasciotomy. 1994 through 1997. *J Am Podiatr Med Assoc* 89:89–93, 1999.
164. Tountas AA, Fornasier VL. Operative treatment of subcalcaneal pain. *Clin Orthop Relat Res* 332:170–178, 1996.
165. Vohra PK, Giorgini RJ, Sobel E, Japour CJ, Villalba MA, Rostkowski T. Long-term follow-up of heel spur surgery. A 10-year retrospective study. *J Am Podiatr Med Assoc* 89:81–88, 1999.
166. Ward WG, Clippinger FW. Proximal medial longitudinal arch incision for plantar fascia release. *Foot Ankle* 8:152–155, 1987.
167. White DL. Plantar fascial release. *J Am Podiatr Med Assoc* 84:607–613, 1994.
168. Barrett SL, Day SV. Endoscopic plantar fasciotomy: two portal endoscopic surgical techniques—clinical results of 65 procedures. *J Foot Ankle Surg* 32:248–256, 1993.
169. Woelffer KE, Figura MA, Sandberg NS, Snyder NS. Five-year follow-up results of instep plantar fasciotomy for chronic heel pain. *J Foot Ankle Surg* 39:218–223, 2000.
170. Urovitz EP, Birk-Urovitz A, Birk-Urovitz E. Endoscopic plantar fasciotomy in the treatment of chronic heel pain. *Can J Surg* 51:281–283, 2008.
171. Chuckpaiwong B, Berkson EM, Theodore GH. Extracorporeal shock wave for chronic proximal plantar fasciitis: 225 patients with results and outcome predictors. *J Foot Ankle Surg* 48:148–155, 2009.
172. Bazzaz R, Ferkel RD. Results of endoscopic plantar fascia release. *Foot Ankle Int* 28:549–556, 2007.
173. Theodore GH, Buch M, Amendola A, Bachmann C, Fleming LL, Zingas C. Extracorporeal shock wave therapy for the treatment of plantar fasciitis. *Foot Ankle Int* 25:290–297, 2004.
174. Saxena A. Uniportal endoscopic plantar fasciotomy: a prospective study on athletic patients. *Foot Ankle Int* 25:882–889, 2004.
175. Lane GD, London B. Heel spur syndrome: a retrospective report on the percutaneous plantar transverse incisional approach. *J Foot Ankle Surg* 43:389–394, 2004.
176. Jerosch J, Schunck J, Liebsch D, Filler T. Indication, surgical technique and results of endoscopic fascial release in plantar fasciitis (E FRPF). *Knee Surg Sports Traumatol Arthrosc* 12:471–477, 2004.
177. Hogan KA, Webb D, Shereff M. Endoscopic plantar fascia release. *Foot Ankle Int* 25:875–881, 2004.
178. Boyle RA, Slater GL. Endoscopic plantar fascia release: a case series. *Foot Ankle Int* 24:176–179, 2003.
179. Krischek O, Rompe JD, Herbsthofner B, Nafe B. [Symptomatic low-energy shock wave therapy in heel pain and radiologically detected plantar heel spur.]. *Z Orthop Ihre Grenzgeb* 136:169–174, 1998.
180. Maier M, Steinborn M, Schmitz C, Stabler A, Kohler S, Pfahler M, Durr HR, Refior HJ. Extracorporeal shock wave application for chronic plantar fasciitis associated with heel spurs: prediction of outcome by magnetic resonance imaging. *J Rheumatol* 27:2455–2462, 2000.
181. Perlick L, Boxberg W, Giebel G. [High energy shock wave treatment of the painful heel spur]. *Unfallchirurg* 101:914–918, 1998.
182. Sierstmann R, Katthagen BD. [5-years lithotripsy of plantar of plantar heel spur: experiences and results—a follow-up study after 36.9 months]. *Z Orthop Ihre Grenzgeb* 136:402–406, 1998. German.
183. Wang CJ, Chen HS, Chen WS, Chen LM. Treatment of painful heels using extracorporeal shock wave. *J Formos Med Assoc* 99:580–583, 2000.
184. Greve JM, Grecco MV, Santos-Silva PR. Comparison of radial shockwaves and conventional physiotherapy for treating plantar fasciitis. *Clinics* 64:97–103, 2009.
185. Gollwitzer H, Diehl P, von Korff A, Rahlfs VW, Gerdesmeyer L. Extracorporeal shock wave therapy for chronic painful heel syndrome: a prospective, double blind, randomized trial assessing the efficacy of a new electromagnetic shock wave device. *J Foot Ankle Surg* 46:348–357, 2007.
186. Wang CJ, Wang FS, Yang KD, Weng LH, Ko JY. Long-term results of extracorporeal shockwave treatment for plantar fasciitis. *Am J Sports Med* 34:592–596, 2006.
187. Malay DS, Pressman MM, Assili A, Kline JT, York S, Buren B, Heyman ER, Borowsky P, LeMay C. Extracorporeal shockwave therapy versus placebo for the treatment of chronic proximal plantar fasciitis: results of a randomized, placebo-controlled, double-blinded, multicenter intervention trial. *J Foot Ankle Surg* 45:196–210, 2006.
188. Landorf KB, Menz HB, Radford JA. Effectiveness of extracorporeal shockwave treatment in 353 patients with chronic plantar fasciitis. *J Am Podiatr Med Assoc* 96:269–270, 2006. author reply 271–262.
189. Kudo P, Dainty K, Clarfield M, Coughlin L, Lavoie P, Lebrun C. Randomized, placebo-controlled, double-blind clinical trial evaluating the treatment of plantar fasciitis with an extracorporeal shockwave therapy (ESWT) device: a North American confirmatory study. *J Orthop Res* 24:115–123, 2006.
190. DiResta J. Effectiveness of extracorporeal shockwave treatment in 353 patients with chronic plantar fasciitis. *J Am Podiatr Med Assoc* 96:270–271, 2006. author reply 271–272.
191. Norris DM, Eickmeier KM, Werber BR. Effectiveness of extracorporeal shockwave treatment in 353 patients with chronic plantar fasciitis. *J Am Podiatr Med Assoc* 95:517–524, 2005.
192. Hyer CF, Vancourt R, Block A. Evaluation of ultrasound-guided extracorporeal shock wave therapy (ESWT) in the treatment of chronic plantar fasciitis. *J Foot Ankle Surg* 44:137–143, 2005.
193. Wilner JM, Strash WW. Extracorporeal shockwave therapy for plantar fasciitis and other musculoskeletal conditions utilizing the Ossatron—an update. *Clin Podiatr Med Surg* 21:441–447, 2004. viii.
194. Wang CJ, Chen HS, Huang TW. Shockwave therapy for patients with plantar fasciitis: a one-year follow-up study. *Foot Ankle Int* 23:204–207, 2002.
195. Strash WW, Perez RR. Extracorporeal shockwave therapy for chronic proximal plantar fasciitis. *Clin Podiatr Med Surg* 19:467–476, 2002.
196. Ogden JA, Alvarez RG, Marlow M. Shockwave therapy for chronic proximal plantar fasciitis: a meta-analysis. *Foot Ankle Int* 23:301–308, 2002.
197. Hammer DS, Rupp S, Kreutz A, Pape D, Kohn D, Seil R. Extracorporeal shockwave therapy (ESWT) in patients with chronic proximal plantar fasciitis. *Foot Ankle Int* 23:309–313, 2002.
198. Chung B, Wiley JP. Extracorporeal shockwave therapy: a review. *Sports Med* 32:851–865, 2002.
199. Buch M, Knorr U, Fleming L, Theodore G, Amendola A, Bachmann C, Zingas C, Siebert WE. [Extracorporeal shockwave therapy in symptomatic heel spurs. An overview.] *Orthopade* 31:637–644, 2002. German.
200. Boddeker R, Schafer H, Haake M. Extracorporeal shockwave therapy (ESWT) in the treatment of plantar fasciitis—a biometrical review. *Clin Rheumatol* 20:324–330, 2001.
201. Heller KD. [Extracorporeal shockwave therapy in heel spur—analysis of the literature.] *Z Orthop Ihre Grenzgeb* 137:0a13–15, 1999. German.
202. Tornese D, Mattei E, Lucchesi G, Bandi M, Ricci G, Melegati G. Comparison of two extracorporeal shock wave therapy techniques for the treatment of painful subcalcaneal spur. A randomized controlled study. *Clin Rehabil* 22:780–787, 2008.
203. Weil LS Jr, Roukis TS, Weil LS, Borrelli AH. Extracorporeal shock wave therapy for the treatment of chronic plantar fasciitis: indications, protocol, intermediate results, and a comparison of results to fasciotomy. *J Foot Ankle Surg* 41:166–172, 2002.
204. Rompe JD, Schoellner C, Nafe B. Evaluation of low-energy extracorporeal shock-wave application for treatment of chronic plantar fasciitis. *J Bone Joint Surg Am* 84-A:335–341, 2002.
205. Gerdesmeyer L, Frey C, Vester J, Maier M, Weil L Jr, Weil L Sr, Russlies M, Stienstra J, Scurran B, Fedder K, Diehl P, Lohrer H, Henne M, Gollwitzer H. Radial extracorporeal shock wave therapy is safe and effective in the treatment of chronic recalcitrant plantar fasciitis: results of a confirmatory randomized placebo-controlled multicenter study. *Am J Sports Med* 36:2100–2109, 2008.
206. Marks W, Jackiewicz A, Witkowski Z, Kot J, Deja W, Lasek J. Extracorporeal shock-wave therapy (ESWT) with a new-generation pneumatic device in the treatment of heel pain. A double blind randomised controlled trial. *Acta Orthop Belg* 74:98–101, 2008.
207. Yu JS, Smith G, Ashman C, Kaeding C. The plantar fasciotomy: MR imaging findings in asymptomatic volunteers. *Skeletal Radiol* 28:447–452, 1999.
208. Wander DS. A retrospective comparison of endoscopic plantar fasciotomy to open plantar fasciotomy with heel spur resection for chronic plantar fasciitis/heel spur syndrome. *J Foot Ankle Surg* 35:183–184, 1996.
209. Barrett SL, Day SV, Pignetti TT, Egly BR. Endoscopic heel anatomy: analysis of 200 fresh frozen specimens. *J Foot Ankle Surg* 34:51–56, 1995.
210. Graves RH, Levin DR, Giacomelli J, White PR, Russell RD. Fluoroscopy-assisted plantar fasciotomy and calcaneal exostectomy: a retrospective study and comparison of surgical techniques. *J Foot Ankle Surg* 33:475–481, 1994.
211. Barrett SL, Day SV, Brown MG. Endoscopic plantar fasciotomy: preliminary study with cadaveric specimens. *J Foot Surg* 30:170–172, 1991.

212. Marafko C. Endoscopic partial plantar fasciotomy as a treatment alternative in plantar fasciitis. *Acta Chir Orthop Traumatol Cech* 74:406–409, 2007.
213. Cheung JT, An KN, Zhang M. Consequences of partial and total plantar fascia release: a finite element study. *Foot Ankle Int* 27:125–132, 2006.
214. Lundeen RO, Aziz S, Burks JB, Rose JM. Endoscopic plantar fasciotomy: a retrospective analysis of results in 53 patients. *J Foot Ankle Surg* 39:208–217, 2000.
215. Sollitto RJ, Plotkin EL, Klein PG, Mullin P. Early clinical results of the use of radiofrequency lesioning in the treatment of plantar fasciitis. *J Foot Ankle Surg* 36:215–219, 1997. discussion 256.
216. Allen BH, Fallat LM, Schwartz SM. Cryosurgery: an innovative technique for the treatment of plantar fasciitis. *J Foot Ankle Surg* 46:75–79, 2007.
217. Weil L Jr, Glover JP, Sr Weil LS. A new minimally invasive technique for treating plantar fasciosis using bipolar radiofrequency: a prospective analysis. *Foot Ankle Spec* 1:13–18, 2008.
218. Cavazos GJ, Khan KH, D'Antoni AV, Harkless LB, Lopez D. Cryosurgery for the treatment of heel pain. *Foot Ankle Int* 30:500–505, 2009.
219. Clement DB, Taunton JE, Smart GW. Achilles tendinitis and peritendinitis: etiology and treatment. *Am J Sports Med* 12:179–184, 1984.
220. Nelen G, Martens M, Burssens A. Surgical treatment of chronic Achilles tendinitis. *Am J Sports Med* 17:754–759, 1989.
221. Stephens MM. Haglund's deformity and retrocalcaneal bursitis. *Orthop Clin North Am* 25:41–46, 1994.
222. Aronow MS. Posterior heel pain (retrocalcaneal bursitis, insertional and non-insertional Achilles tendinopathy). *Clin Podiatr Med Surg* 22:19–43, 2005.
223. Barge-Caballero E, Crespo-Leiro MG, Paniagua-Martin MJ, Muniz J, Naya C, Bouzas-Mosquera A, Pinon-Esteban P, Marzoa-Rivas R, Pazos-Lopez P, Cursack GC, Cuenca-Castillo JJ, Castro-Beiras A. Quinolone-related Achilles tendinopathy in heart transplant patients: incidence and risk factors. *J Heart Lung Transplant* 27:46–51, 2008.
224. Gottschalk AW, Bachman JW. Death following bilateral complete Achilles tendon rupture in a patient on fluoroquinolone therapy: a case report. *J Med Case Reports* 3:1, 2009.
225. Maurin N. [Fluoroquinolone-induced Achilles tendon rupture.]. *Dtsch Med Wochenschr* 133:241–244, 2008. German.
226. Filippucci E, Farina A, Bartolucci F, Spallacci C, Busilacchi P, Grassi W. [Levofloxacin-induced bilateral rupture of the Achilles tendon: clinical and sonographic findings.]. *Reumatismo* 55:267–269, 2003. Italian.
227. Panigrahi R, Longcroft-Wheaton G, Laji K. Bilateral ankle pain and quinolone use: a case of tendon rupture secondary to quinolone use. *Br J Hosp Med (Lond)* 69:168–169, 2008.
228. Lim S, Hossain MA, Park J, Choi SH, Kim G. The effects of enrofloxacin on canine tendon cells and chondrocytes proliferation in vitro. *Vet Res Commun* 32:243–253, 2008.
229. Medrano San Ildefonso M, Mauri Llerda JA, Bruscas Izu C. [Fluoroquinolone-induced tendon diseases.]. *An Med Interna* 24:227–230, 2007. Spanish.
230. Damuth E, Heidebaugh J, Malani PN, Cinti SK. An elderly patient with fluoroquinolone-associated Achilles tendinitis. *Am J Geriatr Pharmacother* 6:264–268, 2008.
231. Shortt P, Wilson R, Erskine I. Tendinitis: the Achilles heel of quinolones!. *Emerg Med J* 23:e63, 2006.
232. Sugimoto T, Kaneko H, Deji N, Koya D. Levofloxacin-induced Achilles tendon rupture in a patient with systemic microscopic polyangiitis. *Mod Rheumatol* 15:217–219, 2005.
233. Yu C, Giuffre B. Achilles tendinopathy after treatment with fluoroquinolone. *Australas Radiol* 49:407–410, 2005.
234. Melhus A. Fluoroquinolones and tendon disorders. *Expert Opin Drug Saf* 4:299–309, 2005.
235. Burkhardt O, Kohnlein T, Pap T, Welte T. Recurrent tendinitis after treatment with two different fluoroquinolones. *Scand J Infect Dis* 36:315–316, 2004.
236. Kowatari K, Nakashima K, Ono A, Yoshihara M, Amano M, Toh S. Levofloxacin-induced bilateral Achilles tendon rupture: a case report and review of the literature. *J Orthop Sci* 9:186–190, 2004.
237. Melhus A, Apelqvist J, Larsson J, Eneroth M. Levofloxacin-associated Achilles tendon rupture and tendinopathy. *Scand J Infect Dis* 35:768–770, 2003.
238. Vanek D, Saxena A, Boggs JM. Fluoroquinolone therapy and Achilles tendon rupture. *J Am Podiatr Med Assoc* 93:333–335, 2003.
239. Schindler C, Pittrow D, Kirch W. Reoccurrence of levofloxacin-induced tendinitis by phenoxymethylpenicillin therapy after 6 months: a rare complication of fluoroquinolone therapy? *Chemotherapy* 49:90–91, 2003.
240. Butler MW, Griffin JF, Quinlan WR, McDonnell TJ. Quinolone-associated tendonitis: a potential problem in COPD? *Ir J Med Sci* 170:198–199, 2001.
241. van der Linden PD, Sturkenboom MC, Herings RM, Leufkens HG, Stricker BH. Fluoroquinolones and risk of Achilles tendon disorders: case-control study. *BMJ* 324:1306–1307, 2002.
242. van der Linden PD, van Puijbroek EP, Feenstra J, Veld BA, Sturkenboom MC, Herings RM, Leufkens HG, Stricker BH. Tendon disorders attributed to fluoroquinolones: a study on 42 spontaneous reports in the period 1988 to 1998. *Arthritis Rheum* 45:235–239, 2001.
243. van der Linden PD, van de Lei J, Nab HW, Knol A, Stricker BH. Achilles tendinitis associated with fluoroquinolones. *Br J Clin Pharmacol* 48:433–437, 1999.
244. Lewis JR, Gums JG, Dickensheets DL. Levofloxacin-induced bilateral Achilles tendonitis. *Ann Pharmacother* 33:792–795, 1999.
245. Kahn MF. Achilles tendinitis and ruptures. *Br J Sports Med* 32:266, 1998.
246. Zabraniecki L, Negrier I, Vergne P, Arnaud M, Bonnet C, Bertin P, Treves R. Fluoroquinolone induced tendinopathy: report of 6 cases. *J Rheumatol* 23:516–520, 1996.
247. Ribard P, Audisio F, Kahn MF, De Bandt M, Jorgensen C, Hayem G, Meyer O, Palazzo E. Seven Achilles tendinitis including 3 complicated by rupture during fluoroquinolone therapy. *J Rheumatol* 19:1479–1481, 1992.
248. Ford LT, DeBender J. Tendon rupture after local steroid injection. *South Med J* 72:827–830, 1979.
249. Hugate R, Pennypacker J, Saunders M, Juliano P. The effects of intratendinous and retrocalcaneal intrabursal injections of corticosteroid on the biomechanical properties of rabbit Achilles tendons. *J Bone Joint Surg Am* 86-A:794–801, 2004.
250. Hamilton B, Remedios D, Loosemore M, Maffulli N. Achilles tendon rupture in an elite athlete following multiple injection therapies. *J Sci Med Sport* 11:566–568, 2008.
251. Hennessy MS, Molloy AP, Sturdee SW. Noninsertional Achilles tendinopathy. *Foot Ankle Clin* 12:617–641, 2007. vi-vii.
252. DeOrio MJ, Easley ME. Surgical strategies: insertional achilles tendinopathy. *Foot Ankle Int* 29:542–550, 2008.
253. Kolodziej P, Glisson RR, Nunley JA. Risk of avulsion of the Achilles tendon after partial excision for treatment of insertional tendinitis and Haglund's deformity: a biomechanical study. *Foot Ankle Int* 20:433–437, 1999.
254. Schepesis AA, Leach RE. Surgical management of Achilles tendinitis. *Am J Sports Med* 15:308–315, 1987.
255. Solan M, Davies M. Management of insertional tendinopathy of the Achilles tendon. *Foot Ankle Clin* 12:597–615, 2007. vi.
256. Wagner E, Gould JS, Kneidel M, Fleisig GS, Fowler R. Technique and results of Achilles tendon detachment and reconstruction for insertional Achilles tendinosis. *Foot Ankle Int* 27:677–684, 2006.
257. Schepesis AA, Wagner C, Leach RE. Surgical management of Achilles tendon overuse injuries. A long-term follow-up study. *Am J Sports Med* 22:611–619, 1994.
258. McGarvey WC, Palumbo RC, Baxter DE, Leibman BD. Insertional Achilles tendinosis: surgical treatment through a central tendon splitting approach. *Foot Ankle Int* 23:19–25, 2002.
259. Chiara Vulpiani M, Guzzini M, Ferretti A. Operative treatment of chronic Achilles tendinopathy. *Int Orthop* 27:307–310, 2003.
260. Calder JD, Saxby TS. Surgical treatment of insertional Achilles tendinosis. *Foot Ankle Int* 24:119–121, 2003.
261. Krishna Sayana M, Maffulli N. Insertional Achilles tendinopathy. *Foot Ankle Clin* 10:309–320, 2005.
262. Carmont MR, Maffulli N. Management of insertional Achilles tendinopathy through a Cincinnati incision. *BMC Musculoskelet Disord* 8:82, 2007.
263. Anderson JA, Suero E, O'Loughlin PF, Kennedy JG. Surgery for retrocalcaneal bursitis: a tendon-splitting versus a lateral approach. *Clin Orthop Relat Res* 466:1678–1682, 2008.
264. Maffulli N, Testa V, Capasso G, Sullo A. Calcific insertional Achilles tendinopathy: reattachment with bone anchors. *Am J Sports Med* 32:174–182, 2004.
265. Gentchos CE, Bohay DR, Anderson JG. Gastrocnemius recession as treatment for refractory achilles tendinopathy: a case report. *Foot Ankle Int* 29:620–623, 2008.
266. Rasmussen S, Christensen M, Mathiesen I, Simonson O. Shockwave therapy for chronic Achilles tendinopathy: a double-blind, randomized clinical trial of efficacy. *Acta Orthop* 79:249–256, 2008.
267. Furia JP. High-energy extracorporeal shock wave therapy as a treatment for chronic noninsertional Achilles tendinopathy. *Am J Sports Med* 36:502–508, 2008.
268. Fridman R, Cain JD, Weil L Jr, Sr Weil L. Extracorporeal shockwave therapy for the treatment of Achilles tendinopathies: a prospective study. *J Am Podiatr Med Assoc* 98:466–468, 2008.
269. Furia JP. High-energy extracorporeal shock wave therapy as a treatment for insertional Achilles tendinopathy. *Am J Sports Med* 34:733–740, 2006.
270. Liu YJ, Wang ZG, Li ZL, Cai X, Zhou M, Wei M, Zhu JL. [Arthroscopically assisted radiofrequency probe to treat achilles tendinitis.]. *Zhonghua Wai Ke Za Zhi* 46:101–103, 2008. Chinese.
271. Tasto JP, Cummings J, Medlock V, Hardesty R, Amiel D. Microtenotomy using a radiofrequency probe to treat lateral epicondylitis. *Arthroscopy* 21:851–860, 2005.
272. Tasto JP, Cummings J, Medlock V, Harwood F, Hardesty R, Amiel D. The tendon treatment center: new horizons in the treatment of tendinosis. *Arthroscopy* 19(Suppl 1):213–223, 2003.
273. Ruch JA. Haglund's disease. *J Am Podiatr Assoc* 64:1000–1003, 1974.
274. Vega MR, Cavolo DJ, Green RM, Cohen RS. Haglund's deformity. *J Am Podiatry Assoc* 74:129–135, 1984.
275. Le TA, Joseph PM. Common exostectomies of the rearfoot. *Clin Podiatr Med Surg* 8:611–617, 1981.
276. Pavlov H, Heneghan MA, Hersh A, Goldman AB, Vigorita V. The Haglund syndrome: initial and differential diagnosis. *Radiology* 144:83–88, 1982.
277. Sofka CM, Adler RS, Positano R, Pavlov H, Luchs JS. Haglund's syndrome: diagnosis and treatment using sonography. *HSS J* 2:27–29, 2006.
278. Reinherz RP, Smith BA, Henning KE. Understanding the pathologic Haglund's deformity. *J Foot Surg* 29:432–435, 1990.
279. Fowler A, Philip JF. Abnormality of the calcaneus as a cause of painful heel: its diagnosis and operative treatment. *Brit J Surg* 32:494–498, 1954.
280. Chauveaux D, Liet P, Le Huec JC, Midy D. A new radiologic measurement for the diagnosis of Haglund's deformity. *Surg Radiol Anat* 13:39–44, 1991.

281. Notari MA, Mittler BE. An investigation of Fowler-Philip's angle in diagnosing Haglund's deformity. *J Am Podiatry Assoc* 74:486–489, 1984.
282. Sammarco GJ, Taylor AL. Operative management of Haglund's deformity in the nonathlete: a retrospective study. *Foot Ankle Int* 19:724–729, 1998.
283. Sella EJ, Caminear DS, McLarney EA. Haglund's syndrome. *J Foot Ankle Surg* 37:110–114, 1998. discussion 173.
284. Jarde O, Quenot P, Trinquier-Lautard JL, Tran-Van F, Vives P. [Haglund disease treated by simple resection of calcaneus tuberosity. An angular and therapeutic study. Apropos of 74 cases with 2 years follow-up.] *Rev Chir Orthop Reparatrice Appar Mot* 83:566–573, 1997. French.
285. Grossman AB. Grand rounds: Haglund's deformity and retrocalcaneal intratendinous spurting. *J Foot Ankle Surg* 36:70, 1997.
286. Nesse E, Finsen V. Poor results after resection for Haglund's heel. Analysis of 35 heels in 23 patients after 3 years. *Acta Orthop Scand* 65:107–109, 1994.
287. Smith LS, Tillo TH. Haglund's deformity in long distance runners. Nine surgical cases. *J Am Podiatr Med Assoc* 78:419–422, 1988.
288. Rutherford RL. Surgical correction of retrocalcaneal bursitis (Haglund's disease). *J Am Podiatry Assoc* 48:538–539, 1958.
289. Jerosch J, Schunck J, Sokkar SH. Endoscopic calcaneoplasty (ECP) as a surgical treatment of Haglund's syndrome. *Knee Surg Sports Traumatol Arthrosc* 15:927–934, 2007.
290. Chen CH, Huang PJ, Chen TB, Cheng YM, Lin SY, Chiang HC, Huang CY, Huang CK. Surgical treatment for Haglund's deformity. *Kaohsiung J Med Sci* 17:419–422, 2001.
291. Maynou C, Mestdagh H, Dubois HH, Petroff E, Elise S. [Is calcaneal osteotomy justified in Haglund's disease?]. *Rev Chir Orthop Reparatrice Appar Mot* 84:734–738, 1998. French.
292. Perlman MD. Enlargement of the entire posterior aspect of the calcaneus: treatment with the Keck and Kelly calcaneal osteotomy. *J Foot Surg* 31:424–433, 1992.
293. Green AH, Hass MI, Tubridy SP, Goldberg MM, Perry JB. Calcaneal osteotomy for retrocalcaneal exostosis. *Clin Podiatr Med Surg* 8:659–665, 1991.
294. Miller AE, Vogel TA. Haglund's deformity and the Keck and Kelly osteotomy: a retrospective analysis. *J Foot Surg* 28:23–29, 1989.
295. Jerosch J, Nasef NM. Endoscopic calcaneoplasty—rationale, surgical technique, and early results: a preliminary report. *Knee Surg Sports Traumatol Arthrosc* 11:190–195, 2003.
296. van Dijk CN, van Dyk GE, Scholten PE, Kort NP. Endoscopic calcaneoplasty. *Am J Sports Med* 29:185–189, 2001.
297. Marui T, Yamamoto T, Akisue T, Hitora T, Kawamoto T, Nagira K, Yoshiya S, Kurosaka M. Neurilemmoma in the foot as a cause of heel pain: a report of two cases. *Foot Ankle Int* 25:107–111, 2004.
298. Mabin D. [Distal nerve compression of the leg. Clinical and electrophysiologic study.]. *Neurophysiol Clin* 27:9–24, 1997. French.
299. Kim J, Dellon AL. Neuromas of the calcaneal nerves. *Foot Ankle Int* 22:890–894, 2001.
300. Mezrow CK, Sanger JR, Matloub HS. Acute tarsal tunnel syndrome following partial avulsion of the flexor hallucis longus muscle: a case report. *J Foot Ankle Surg* 41:243–246, 2002.
301. Oh SJ, Meyer RD. Entrapment neuropathies of the tibial (posterior tibial) nerve. *Neurol Clin* 17:593–615, 1999. vii.
302. Dellon AL, Kim J, Spaulding CM. Variations in the origin of the medial calcaneal nerve. *J Am Podiatr Med Assoc* 92:97–101, 2002.
303. Chang CW, Wang YC, Hou WH, Lee XX, Chang KF. Medial calcaneal neuropathy is associated with plantar fasciitis. *Clin Neurophysiol* 118:119–123, 2007.
304. Fredericson M, Standage S, Chou L, Matheson G. Lateral plantar nerve entrapment in a competitive gymnast. *Clin J Sport Med* 11:111–114, 2001.
305. Chundru U, Liebeskind A, Seidemann F, Fogel J, Franklin P, Beltran J. Plantar fasciitis and calcaneal spur formation are associated with abductor digiti minimi atrophy on MRI of the foot. *Skeletal Radiol* 37:505–510, 2008.
306. Chan LK, Lui TH, Chan KB. Anatomy of the portal tract for endoscopic decompression of the first branch of the lateral plantar nerve. *Arthroscopy* 24:1284–1288, 2008.
307. Ebskov L, Rasmussen PB, Erichsen M. [Isolated lesions to the sural nerve. Causes, claims review procedure and compensation.] *Ugeskr Laeger* 170:2885–2887, 2008. Danish.
308. Husson JL, Mathieu M, Briand B, Meadeb J, Barumbi O, Masse A. [Syndrome of compression of the external saphenous nerve (or the sural nerve)]. *Acta Orthop Belg* 55:491–497, 1989. French.
309. Willis JD, Carter PM. Tibial nerve entrapment and heel pain caused by a Baker's cyst. *J Am Podiatr Med Assoc* 88:310–311, 1998.
310. Dellon AL, Mackinnon SE. Chronic nerve compression model for the double crush hypothesis. *Ann Plast Surg* 26:259–264, 1991.
311. Osterman AL. The double crush syndrome. *Orthop Clin North Am* 19:147–155, 1988.
312. Upton AR, McComas AJ. The double crush in nerve entrapment syndromes. *Lancet* 2:359–362, 1973.
313. Golovchinsky V. Double crush syndrome in lower extremities. *Electromyogr Clin Neurophysiol* 38:115–120, 1998.
314. Baxter DE, Thigpen CM. Heel pain—operative results. *Foot Ankle* 5:16–25, 1984.
315. Murphy PC, Baxter DE. Nerve entrapment of the foot and ankle in runners. *Clin Sports Med* 4:753–763, 1985.
316. MacFarlane IJA, DuToit SN. A ganglion causing tarsal tunnel syndrome. *S Afr Med J* 48:256–260, 1974.
317. Goodman CR, Kehr LE. Bilateral tarsal tunnel syndrome. *J Am Podiatr Assoc* 73:256–260, 1983.
318. Tres GS, Lisboa HR, Syllos R, Canani LH, Gross JL. Prevalence and characteristics of diabetic polyneuropathy in Passo Fundo, South of Brazil. *Arq Bras Endocrinol Metabol* 51:987–992, 2007.
319. van Heel DA, Levitt NS, Winter TA. Diabetic neuropathic cachexia: the importance of positive recognition and early nutritional support. *Int J Clin Pract* 52:591–592, 1998.
320. Chaudhry V, Russell J, Belzberg A. Decompressive surgery of lower limbs for symmetrical diabetic peripheral neuropathy. *Cochrane Database Syst Rev* 3. CD006152.
321. Zahir KS, Zahir FS, Thomas JG, Dudrick SJ. The double-crush phenomenon—an unusual presentation and literature review. *Conn Med* 63:535–538, 1999.
322. Kale B, Yuksel F, Celikoz B, Sirvanci S, Ergun O, Arbak S. Effect of various nerve decompression procedures on the functions of distal limbs in streptozotocin-induced diabetic rats: further optimism in diabetic neuropathy. *Plast Reconstr Surg* 111:2265–2272, 2003.
323. Barker AR, Rosson GD, Dellon AL. Outcome of neurolysis for failed tarsal tunnel surgery. *J Reconstr Microsurg* 24:111–118, 2008.
324. Goldman SM. Neurogenic positional pedal neuritis. Common pedal manifestations of spinal stenosis. *J Am Podiatr Med Assoc* 93:174–184, 2003.
325. Praet SF, Louwerens JW. The influence of shoe design on plantar pressures in neuropathic feet. *Diabetes Care* 26:441–445, 2003.
326. Lee BY, Thurmon TF. Nutritional disorders among workers in North China during national turmoil. *Ann Nutr Metab* 45:175–180, 2001.
327. Lichniak JE. The heel in systemic disease. *Clin Podiatr Med Surg* 7:225–241, 1990.
328. Labib SA, Gould JS, Rodriguez-del-Rio FA, Lyman S. Heel pain triad (HPT): the combination of plantar fasciitis, posterior tibial tendon dysfunction and tarsal tunnel syndrome. *Foot Ankle Int* 23:212–220, 2002.
329. Conflitti JM, Tarquinio TA. Operative outcome of partial plantar fasciectomy and neurolysis to the nerve of the abductor digiti minimi muscle for recalcitrant plantar fasciitis. *Foot Ankle Int* 25:482–487, 2004.
330. Watson TS, Anderson RB, Davis WH, Kiezbak GM. Distal tarsal tunnel release with partial plantar fasciotomy for chronic heel pain: an outcome analysis. *Foot Ankle Int* 23:530–537, 2002.
331. Resnick RB, Hudgins LC, Buschmann WR, Kummer FJ, Jahss MH. Analysis of the heel pad fat in rheumatoid arthritis. *Foot Ankle Int* 20:481–484, 1999.
332. Jones RO, Chen JB, Pitcher D, Gebhart-Mueller EY, Mueller PQ. Rheumatoid nodules affecting both heels with surgical debulking: a case report*. *J Am Podiatr Med Assoc* 86:179–182, 1996.
333. Jahss MH. Foot and ankle pain resulting from rheumatic conditions. *Curr Opin Rheumatol* 4:233–240, 1992.
334. Bouysset M, Tebib JG, Vianey JC, Berthier M, Nemoz JC, Chaumentin G, Schnepf J, Llorca G, Bouvier M. [Heel involvement in rheumatoid polyarthritides.]. *Rev Rhum Mal Osteoartic* 57:799–803, 1990. French.
335. Bouysset M, Tebib J, Weil G, Noel E, Colson F, Llorca G, Lejeune E, Bouvier M. The rheumatoid heel: its relationship to other disorders in the rheumatoid foot. *Clin Rheumatol* 8:208–214, 1989.
336. Dimonte P, Light H. Pathomechanics, gait deviations, and treatment of the rheumatoid foot: a clinical report. *Phys Ther* 62:1148–1156, 1982.
337. Raymakers R. The painful foot. *Practitioner* 215:61–68, 1975.
338. Furey JG. Plantar fasciitis. The painful heel syndrome. *J Bone Joint Surg Am* 57:672–673, 1975.
339. Vidigal E, Jacoby RK, Dixon AS, Ratliff AH, Kirkup J. The foot in chronic rheumatoid arthritis. *Ann Rheum Dis* 34:292–297, 1975.
340. Gerster JC. Plantar fasciitis and Achilles tendinitis among 150 cases of seronegative spondylarthritis. *Rheumatol Rehabil* 19:218–222, 1980.
341. Lipscomb PR. Surgery of the rheumatoid foot: preferable procedures. *Rev Chir Orthop Reparatrice Appar Mot* 67:375–382, 1981.
342. Riel KA, Bernet P. [Therapy-resistant heel pain—an indication for surgery in sports traumatology.]. *Sportverletz Sportschaden* 4:121–124, 1990. German.
343. Forestier J, Lagier R. Ankylosing hyperostoses of the spine. *Clin Orthop* 74:65–83, 1971.
344. Lehman TJ. Enthesitis, arthritis, and heel pain. *J Am Podiatr Med Assoc* 89:18–19, 1999.
345. Leirisalo-Repo M. Prognosis, course of disease, and treatment of the spondyloarthropathies. *Rheum Dis Clin North Am* 24:737–751, 1998. viii.
346. Salvarani C, Cantini F, Olivieri I, Macchioni P, Niccoli L, Padula A, Ferri S, Portioli I. Isolated peripheral enthesitis and/or dactylitis: a subset of psoriatic arthritis. *J Rheumatol* 24:1106–1110, 1997.
347. Gadzhinova LD, Shubin SV, Mach ES, Urumova MM, Pushkova OV, Aliab'eva AP. [The local therapy of enthesitis and bursitis of the calcaneal area in seronegative spondylarthritis.]. *Ter Arkh* 69:47–49, 1997. Russian.
348. Scherer PR, Gordon D, Kashanian A, Belvill A. Misdiagnosed recalcitrant heel pain associated with HLA-B27 antigen. *J Am Podiatr Med Assoc* 85:538–542, 1995.
349. Deesomchok U, Tumrasvin T. Clinical comparison of patients with ankylosing spondylitis, Reiter's syndrome and psoriatic arthritis. *J Med Assoc Thai* 76:61–70, 1993.
350. Dougados M, van der Linden S, Juhlin R, Huitfeldt B, Amor B, Calin A, Cats A, Dijkmans B, Olivieri I, Pasero G, Veys E, Zeidler H. The European Spondylarthropathy Study Group preliminary criteria for the classification of spondylarthropathy. *Arthritis Rheum* 34:1218–1227, 1991.
351. Khan MA, van der Linden SM. A wider spectrum of spondyloarthropathies. *Semin Arthritis Rheum* 20:107–113, 1990.

352. Turlik MA. Seronegative arthritis as a cause of heel pain. *Clin Podiatr Med Surg* 7:369–375, 1990.
353. Lopez Longo FJ, Monteagudo Saez I, Cobeta Garcia JC, Prados Bueno R, de Inocencio Arocena J, Maroto Alvaro E, Garcia Fernandez EJ. [Reiter's syndrome: considerations on the frequency and mid-term course of its juvenile form.]. *An Esp Pediatr* 29:298–301, 1988. Spanish.
354. Job-Deslandre C, Menkes CJ, Godran A, Amor B. [Ankylosing spondylitis with juvenile onset. Study of 62 cases.]. *Rev Rhum Mal Osteoartic* 54:209–212, 1987. French.
355. Doury P, Eulry F, Pattin S. [Clinical aspects of reactive arthritis caused by Chlamydia]. *Rev Rhum Mal Osteoartic* 50:753–757, 1983. French.
356. Hochberg MC, Borenstein DG, Arnett FC. The absence of back pain in classical ankylosing spondylitis. *Johns Hopkins Med J* 143:181–183, 1978.
357. Hidle I. [Heel pain as a symptom in rheumatic diseases]. *Tidsskr Nor Laegeforen* 96:504–505, 1976. Norwegian.
358. Resnick D, Niwayama G. Ankylosing spondylitis. In *Diagnosis of Bone and Joint Disorders*, ed 3, pp 1047–1053, edited by D Resnick, WB Saunders, Philadelphia, 1995.
359. Resnick D. Psoriatic arthritis. In *Diagnosis of Bone and Joint Disorders*, ed 3, pp 1082–1086, edited by D Resnick, WB Saunders, Philadelphia, 1995.
360. Mata S, Fortin PR, Fitzcharles MA, Starr MR, Joseph L, Watts CS, Gore B, Rosenberg E, Chhem RK, Esdaile JM. A controlled study of diffuse idiopathic skeletal hyperostosis. Clinical features and functional status. *Medicine (Baltimore)* 76:104–117, 1997.
361. Harvey CK. Fibromyalgia. Part II. Prevalence in the podiatric patient population. *J Am Podiatr Med Assoc* 83:416–417, 1993.
362. Calmels C, Eulry F, Lechevalier D, Dubost JJ, Ristori JM, Sauvezie B, Bussiere JL. [Involvement of the foot in reactive arthritis. A retrospective study of 105 cases]. *Rev Rhum Ed Fr* 60:324–329, 1993. French.
363. Scutellari PN, Orzincolo C, Princivale M, Franceschini F. [Diffuse idiopathic skeletal hyperostosis. Review of diagnostic criteria and analysis of 915 cases.]. *Radiol Med (Torino)* 83:729–736, 1992. Italian.
364. Kung EE, Glauser T. [Ulcerating gout tophi. Surgical therapy in a patient with hyperuricemia, hyperlipidemia and alcohol abuse.]. *Hautarzt* 42:461–463, 1991. German.
365. Resnick D, Niwayama G. Gouty arthritis. In *Diagnosis of Bone and Joint Disorders*, ed 3, pp 1511–1551, edited by D Resnick, WB Saunders, Philadelphia, 1995.
366. Resnick D. Diffuse idiopathic skeletal hyperostosis. In *Diagnosis of Bone and Joint Disorders*, ed 3, pp 1471–1475, edited by D Resnick, WB Saunders, Philadelphia, 1995 (DISH).
367. Malhotra CM, Lally EV, Buckley WM. Ossification of the plantar fascia and peroneus longus tendons in a diffuse skeletal hyperostosis (DISH). *J Rheumatol* 13:215–218, 1986.
368. Garber EK, Silver S. Pedal manifestations of DISH. *Foot Ankle* 3:12–16, 1982.
369. Ho HH, Yu KH, Chen JY, Lin JL, Wu YJ, Luo SF, Liou LB. Coexisting ankylosing spondylitis and gouty arthritis. *Clin Rheumatol* 26:1655–1661, 2007.
370. Helliwell PS. Relationship of psoriatic arthritis with the other spondyloarthropathies. *Curr Opin Rheumatol* 16:344–349, 2004.
371. Gladman DD, Cook RJ, Schentag C, Feletar M, Inman RI, Hitchon C, Karsh J, Klinkhoff AV, Maksymowych WP, Mosher DP, Nair B, Stone MA. The clinical assessment of patients with psoriatic arthritis: results of a reliability study of the spondyloarthritis research consortium of Canada. *J Rheumatol* 31:1126–1131, 2004.
372. De Simone C, Guerriero C, Giampetruzzi AR, Costantini M, Di Gregorio F, Amerio P. Achilles tendinitis in psoriasis: clinical and sonographic findings. *J Am Acad Dermatol* 49:217–222, 2003.
373. Carves C, Duquenois A, Toutain F, Trioche P, Zarnitski C, Le Roux P, Le Luyer B. Gouty tendinitis revealing glycogen storage disease Type Ia in two adolescents. *Joint Bone Spine* 70:149–153, 2003.
374. Sampaio-Barros PD, Bertolo MB, Kraemer MH, Marques-Neto JF, Samara AM. Undifferentiated spondyloarthropathies: a 2-year follow-up study. *Clin Rheumatol* 20:201–206, 2001.
375. Elkayam O, Ophir J, Yaron M, Caspi D. Psoriatic arthritis: interrelationships between skin and joint manifestations related to onset, course and distribution. *Clin Rheumatol* 19:301–305, 2000.
376. El Hassani S, Sawsen MF, Radouane N, Hajjaj-Hassouni N. Heel pain in rheumatology outpatients. A review of 100 cases. *Joint Bone Spine* 69:235–236, 2002.
377. Burns PR, Scanlan RL, Zgonis T, Lowery C. Pathologic conditions of the heel: tumors and arthritides. *Clin Podiatr Med Surg* 22:115–136, 2005. vii–viii.
378. Yozsa S, Lehnert B, Resnick D. Imaging of the rearfoot. *J Am Podiatr Med Assoc* 89:292–301, 1999.
379. Lokiec F, Wientroub S. Calcaneal osteochondritis: a new overuse injury. *J Pediatr Orthop B* 7:243–245, 1998.
380. O'Duffy EK, Clunie GP, Gacinovic S, Edwards JC, Bomanji JB, Eil PJ. Foot pain: specific indications for scintigraphy. *Br J Rheumatol* 37:442–447, 1998.
381. Tudor GR, Finlay D, Allen MJ, Belton I. The role of bone scintigraphy and plain radiography in intractable plantar fasciitis. *Nucl Med Commun* 18:853–856, 1997.
382. Dasgupta B, Bowles J. Scintigraphic localisation of steroid injection site in plantar fasciitis. *Lancet* 346:1400–1401, 1995.
383. Lin WY, Wang SJ, Lang JL, Hsu CY, Kao CH, Liao SQ, Yeh HW. Bone scintigraphy in evaluation of heel pain in Reiter's disease: compared with radiography and clinical examination. *Scand J Rheumatol* 24:18–21, 1995.
384. Smith SD, Young-Paden B, Smith SB, Ellis WN. Fatigue perturbation of the os calcis. *J Foot Ankle Surg* 33:402–410, 1994.
385. Intenzo CM, Wapner KL, Park CH, Kim SM. Evaluation of plantar fasciitis by three-phase bone scintigraphy. *Clin Nucl Med* 16:325–328, 1991.
386. Nussbaum AR, Treves ST, Micheli L. Bone stress lesions in ballet dancers: scintigraphic assessment. *AJR Am J Roentgenol* 150:851–855, 1988.
387. Williams PL, Smibert JG, Cox R, Mitchell R, Klenerman L. Imaging study of the painful heel syndrome. *Foot Ankle* 7:345–349, 1987.
388. Vasavada PJ, DeVries DF, Nishiyama H. Plantar fasciitis—early blood pool images in diagnosis of inflammatory process. *Foot Ankle* 5:74–76, 1984.
389. Graham CE. Painful heel syndrome: rationale of diagnosis and treatment. *Foot Ankle* 3:261–267, 1983.
390. Fox R, Calin A, Gerber RC, Gibson D. The chronicity of symptoms and disability in Reiter's syndrome. An analysis of 131 consecutive patients. *Ann Intern Med* 91:190–193, 1979.
391. Omev ML, Micheli LJ. Foot and ankle problems in the young athlete. *Med Sci Sports Exerc* 31:S470–S486, 1999.
392. Bencardino J, Rosenberg ZS, Delfaut E. MR imaging in sports injuries of the foot and ankle. *Magn Reson Imaging Clin N Am* 7:131–149, 1999. ix.
393. Matheson GO, Macintyre JG, Taunton JE, Clement DB, Lloyd-Smith R. Musculoskeletal injuries associated with physical activity in older adults. *Med Sci Sports Exerc* 21:379–385, 1989.
394. Schubert JM. Calcaneal fractures. In *Trauma of the Foot and Ankle*, pp 535–574, edited by B Scurran, Churchill-Livingstone, New York, 1996.
395. Carey EJ, Lance EM, Wade PA. Extra-articular fractures of the calcaneus. *J Trauma* 5:363–365, 1965.
396. Lungstadaas S. Treatment of avulsion fractures of the tuber calcanei. *Acta Chir Scand* 137:579, 1971.
397. Lowy M. Avulsion fractures of the calcaneus. *J Bone Joint Surg* 51B:494–497, 1969.
398. Miller WE, Lichtblau PO. The smashed heel. *South Med J* 58:1229–1237, 1965.
399. Jung HG, Yoo MJ, Kim MH. Late sequelae of secondary Haglund's deformity after malunion of tongue type calcaneal fracture: report of two cases. *Foot Ankle Int* 23:1014–1017, 2002.
400. Burks JB, Buk A. Bilateral fractures of the infracalcaneal exostosis. *J Foot Ankle Surg* 42:43–44, 2003.
401. Worthen BM, Yanklowitz B. The pathophysiology and treatment of stress fractures in military personnel. *J Am Podiatr Assoc* 68:317–325, 1978.
402. Greany RB, Gerber FH, Laughlin RL, Kmet JP, Metz CD, Kilcheski TS, Rao BR, Silverman ED. Distribution and natural history of stress fractures in US marine recruits. *Radiology* 146:339–346, 1983.
403. Schubert JM. Calcaneal stress fractures: a pathomechanical etiology. In *Reconstructive Surgery of the Foot and Leg: Update 98*, pp 81–87, edited by SJ Miller, The Podiatry Institute, Tucker, GA, 1998.
404. Tanz SS. Heel pain. *Clin Orthop* 28:169–178, 1963.
405. Hoffman SJ, Thul JR. Fractures of the calcaneus secondary to heel spur surgery. An analysis and case report. *J Am Podiatr Med Assoc* 75:267–271, 1985.
406. Bordelon RL. Subcalcaneal pain: present status, evaluation, and management. *Instr Course Lect* 33:283–287, 1984.
407. Zeiss J, Ebraheim N, Rusin J, Coombs RJ. Magnetic resonance imaging of the calcaneus: normal anatomy and application in calcaneal fractures. *Foot Ankle* 11:264–273, 1991.
408. Coughlin RR. Common injuries of the foot. Often more than 'just a sprain.' *Postgrad Med* 86:175–179, 182, 185, 1989.
409. Silver DA, Kerr PS, Atkins RM, Andrews HS. Fractures of the calcaneum. *J Bone Joint Surg Br* 75:838, 1993.
410. Manoli A, Harper MC, Fitzgibbons TC, McKernan DJ. Calcaneal fracture after cortical bone removal. *Foot Ankle* 13:523–525, 1992.
411. Weber JM, Vidt LG, Gehl RS, Montgomery T. Calcaneal stress fractures. *Clin Podiatr Med Surg* 22:45–54, 2005.
412. Fishco WD, Stiles RG. Atypical heel pain. Hyperparathyroidism-induced stress fracture of the calcaneus. *J Am Podiatr Med Assoc* 89:413–418, 1999.
413. Blaser KU, Aeschlimann A, Gerber B, German. [Diabetic osteoarthropathy of the foot.]. *Z Rheumatol* 49:224–226, 1990.
414. El-Khoury GY, Kathol MH. Neuropathic fractures in patients with diabetes mellitus. *Radiology* 134:313–316, 1980.
415. Griffiths HJ. Trauma to the ankle and foot. *Crit Rev Diagn Imaging* 26:45–105, 1986.
416. Silver DA, Kerr PS, Andrews HS, Atkins RM. Heel pad thickness following calcaneal fractures: ultrasound findings. *Injury* 25:39–40, 1994.
417. Hess M, Booth B, Laughlin RT. Calcaneal avulsion fractures: complications from delayed treatment. *Am J Emerg Med* 26:254, 2008. e1–4.
418. Ozdemir H, Ozdemir A, Soyucu Y, Urguden M. The role of bone scintigraphy in determining the etiology of heel pain. *Ann Nucl Med* 16:395–401, 2002.
419. Ahstrom JP. Spontaneous rupture of the plantar fascia. *Am J Sports Med* 16:306–307, 1988.
420. Pai VS. Rupture of the plantar fascia. *J Foot Ankle Surg* 35:39–40, 1996.
421. Theodorou DJ, Theodorou SJ, Kakitsubata Y, Lektrakul N, Gold GE, Roger B, Resnick D. Plantar fasciitis and fascial rupture: MR imaging findings in 26 patients supplemented with anatomic data in cadavers. *Radiographics* 20 Spec No 2000:S181–S197, 2000.
422. Kaminsky SL, Corcoran D, Chubb WF, Pulla RJ. Myositis ossificans: pedal manifestations. *J Foot Surg* 31:173–181, 1992.
423. Berlin SJ, Mirkin GS, Tubridy SP. Tumors of the heel. *Clin Podiatr Med Surg* 7:307–321, 1990.
424. Freedman DM, Henderson RC. Metastatic breast carcinoma to the os calcis presenting as heel pain. *South Med J* 88:232–234, 1995.

425. Gisserot O, Jaureguiberry JP, Carli P, Paris JF, Jaubert D, Chagnon A. Heel pain as the inaugural manifestation of metastatic prostate cancer. *Rev Rhum Engl Ed* 63:870–871, 1996.
426. Groves MJ, Stiles RG. Metastatic breast cancer presenting as heel pain. *J Am Podiatr Med Assoc* 88:400–405, 1998.
427. Harman RR, Matthews CN. Painful piezogenic pedal papules. *Br J Dermatol* 90:573–574, 1974.
428. Kosinski M, Lilja E. Infectious causes of heel pain. *J Am Podiatr Med Assoc* 89:20–23, 1999.
429. Llauger J, Palmer J, Monill JM, Franquet T, Bague S, Roson N. MR imaging of benign soft-tissue masses of the foot and ankle. *Radiographics* 18:1481–1498, 1998.
430. Nierenberg G, Hoffman A, Engel A, Stein H. Pseudoaneurysm with an arteriovenous fistula of the tibial vessels after plantar fasciotomy: a case report. *Foot Ankle Int* 18:524–525, 1997.
431. Schlappner OL, Wood MG, Gerstein W, Gross PR. Painful and nonpainful piezogenic pedal papules. *Arch Dermatol* 106:729–733, 1972.
432. Chen ML, Graf P, Masotto M, Shihabi NS. Fibrosarcoma of the foot masquerading as plantar fasciitis. *J Am Podiatr Med Assoc* 92:507–511, 2002.
433. Dogan A, Algun E, Kisli E, Harman M, Kosem M, Tosun N. Calcaneal brown tumor with primary hyperparathyroidism caused by parathyroid carcinoma: an atypical localization. *J Foot Ankle Surg* 43:248–251, 2004.
434. Akman S, Gur B, Seckin F, Ozturk I. [A case of bilateral unicameral bone cyst of the calcaneus and surgical outcome.]. *Acta Orthop Traumatol Turc* 36:265–267, 2002. Turkish.
435. Hatori M, Hosaka M, Ehara S, Kokubun S. Imaging features of intraosseous lipomas of the calcaneus. *Arch Orthop Trauma Surg* 121:429–432, 2001.
436. Polat O, Saglik Y, Adiguzel HE, Arıkan M, Yildiz HY. Our clinical experience on calcaneal bone cysts: 36 cysts in 33 patients. *Arch Orthop Trauma Surg* 129:1489–1494, 2008.
437. Asnes RS, Berdon WE, Bassett CA. Hypophosphatemic rickets in an adolescent cured by excision of a nonossifying fibroma. *Clin Pediatr (Phila)* 20:646–648, 1981.
438. Barbieri L. [On 2 rare diseases of the heel: bone cysts and Paget's disease.]. *Minerva Ortop* 20:328–332, 1969. Italian.
439. Kim CW, Shea K, Chambers HG. Heel pain in children. Diagnosis and treatment. *J Am Podiatr Med Assoc* 89:67–74, 1999.
440. Krivickas LS. Anatomical factors associated with overuse sports injuries. *Sports Med* 24:132–146, 1997.
441. Madden CC, Mellion MB. Sever's disease and other causes of heel pain in adolescents. *Am Fam Physician* 54:1995–2000, 1996.
442. Winiker H, Scharli AF. Hematogenous calcaneal osteomyelitis in children. *Eur J Pediatr Surg* 1:216–220, 1991.
443. Micheli LJ, Ireland ML. Prevention and management of calcaneal apophysitis in children: an overuse syndrome. *J Pediatr Orthop* 7:34–38, 1987.
444. Cassas KJ, Cassettari-Wayhs A. Childhood and adolescent sports-related overuse injuries. *Am Fam Physician* 73:1014–1022, 2006.
445. Ishikawa SN. Conditions of the calcaneus in skeletally immature patients. *Foot Ankle Clin* 10:503–513, 2005. vi.
446. Hendrix CL. Calcaneal apophysitis (Sever disease). *Clin Podiatr Med Surg* 22:55–62, 2005. vi.
447. Adirim TA, Cheng TL. Overview of injuries in the young athlete. *Sports Med* 33:75–81, 2003.
448. Volpon JB, de Carvalho Filho G. Calcaneal apophysitis: a quantitative radiographic evaluation of the secondary ossification center. *Arch Orthop Trauma Surg* 122:338–341, 2002.
449. Wooten B, Uhl TL, Chandler J. Use of an orthotic device in the treatment of posterior heel pain. *J Orthop Sports Phys Ther* 11:410–413, 1990.
450. Hosgoren B, Koktencer A, Dilmen G. Ultrasonography of the calcaneus in Sever's disease. *Indian Pediatr* 42:801–803, 2005.
451. Peck DM. Apophyseal injuries in the young athlete. *Am Fam Physician* 51:1891–1895, 1995. 1897–1898.
452. Griffiths HJ. Radiology of Paget's disease. *Curr Opin Radiol* 4:124–128, 1992.
453. Mazzocchi M, Onesti MG, Pasquini P, La Porta R, Innocenzi D, Scuderi N. Giant fibrolipoma in the leg—a case report. *Anticancer Res* 26:3649–3654, 2006.
454. Rossi T, Levitsky K. Osteoid osteoma of the calcaneus: an unusual cause of hindfoot pain in an adolescent athlete. *J Athl Train* 31:71–73, 1996.
455. Miyayama H, Sakamoto K, Ide M, Ise K, Hirota K, Yasunaga T, Ishihara A. Aggressive osteoblastoma of the calcaneus. *Cancer* 71:346–353, 1993.
456. Rogoff RS, Tinkle JD, Bartis DG. Unusual presentation of calcaneal osteomyelitis. Twenty-five years after inoculation. *J Am Podiatr Med Assoc* 87:125–130, 1997.
457. Rai RK, Londhe S, Sinha S, Campbell AC, Aburiziq IS. Spontaneous bifocal *Clostridium septicum* gas gangrene. *J Bone Joint Surg Br* 83:115–116, 2001.
458. Abdelwahab IF, Klein MJ, Hermann G, Abdul-Quader M. Focal tuberculous osteomyelitis of the calcaneus secondary to direct extension from an infected retrocalcaneal bursa. *J Am Podiatr Med Assoc* 95:285–290, 2005.
459. Harwell JI, Fisher D. Pediatric septic bursitis: case report of retrocalcaneal infection and review of the literature. *Clin Infect Dis* 32:E102–E104, 2001.
460. Varshney MK, Trikha V, Gupta V. Isolated tuberculosis of Achilles tendon. *Joint Bone Spine* 74:103–106, 2007.
461. Gbadoe AD, Dogba A, Dagnra AY, Atakouma Y, Tekou H, Assimadi JK. [Acute osteomyelitis in the child with sickle cell disease in a tropical zone: value of oral fluoroquinolones.]. *Arch Pediatr* 8:1305–1310, 2001. French.
462. Treiman GS, Oderich GS, Ashrafi A, Schneider PA. Management of ischemic heel ulceration and gangrene: an evaluation of factors associated with successful healing. *J Vasc Surg* 31:1110–1118, 2000.